



**DATE PRESENTING CLINICAL SIGNS**

2/15/23

Patient presented 1/25/23 for S/R with slight bilateral submandibular LN enlargement (~ 1 & 1/2 cms). Patient then came in 2/15/23 with greater bilateral submandibular LN enlargement. R side 3 x 5.2 cm and L side 3 x 5.5 cm. Both are irregular and firm but not painful to patient. No other LN enlargement palpated on PE. Patient is now drooling and panting more than usual. ~ 8 lb weight loss from 1/25/23-2/15/23 but patient did just board for a week while owners were away and is an active service dog.

**INTERPRETED BY**

L.D. McGill, DVM,  
Ph.D, DACVP

Bilaterally enlarged submandibular LNs. Blood work last done 1/11/23 WNL except slightly low WBC count (4.62K/ $\mu$ L).

**PATIENT**

Babe Elacqua

**CYTOLOGY SUBMISSION**  
FNA of Dermal

**SPECIES**

Canine

**OBSERVATIONS**

Submandibular lymph nodes: Submitted are 29 excellent images of excellent collections of cells from the submandibular lymph nodes in Babe. The cellularity is almost entirely round cells with minimal cytoplasm with the large nuclei. The nuclei are 2 to 4 times the size of red blood cells. Nucleoli are prominent and irregular. There are scattered small lymphocytes in the collection. Some of the lymphoid cells are smudged and uninterpretable. There are scattered mitotic figures.

**BREED**

Golden doodle

**SEX**

Male Neutered

**INTERPRETATION OF THE FINDINGS & FURTHER RECOMMENDATIONS**

Submandibular lymph node - Consistent with early high-grade lymphoma.

**AGE**

8y

**COMMENTS**

The cellularity in this collection is an extremely good collection of cells that strongly suggests the likelihood of an early high-grade lymphoma. Degeneration is occurring secondarily. The degeneration is occurring where cells are smudged during processing. There are adequate numbers of cells that suggest high-grade lymphoma with irregular nucleoli that suggest lymphoma. If chemotherapy is contemplated, then immunophenotyping of the cells to confirm the specific cell type may be beneficial for prognosis. The slides may be submitted for PARR testing or new slides that are not stained can be submitted for immunocytochemistry staining. Flow cytometry can be beneficial but will require a repeat collection of cells prior to submission to the laboratory. Contacting the laboratory to confirm how to submit flow cytometry samples is encouraged. An unfavorable prognosis is warranted but there is a possibility that Babe may respond to therapy early in treatment. Consultation with an oncologist may be beneficial.

**WEIGHT**

101 lbs

**HOSPITAL NAME**

Central Veterinary  
Hospital

**REFERRING VET**

Dr. Karen Krause

**INVOICE NUMBER**

40660



**DATE**

2/15/23

**INTERPRETED BY**

L.D. McGill, DVM,  
Ph.D., DACVP

**PATIENT**

Babe Elacqua

**SPECIES**

Canine

**BREED**

Golden doodle

**SEX**

Male Neutered

**AGE**

8y

**WEIGHT**

101 lbs

**HOSPITAL NAME**

Central Veterinary  
Hospital

**REFERRING VET**

Dr. Karen Krause

**INVOICE NUMBER**

40660

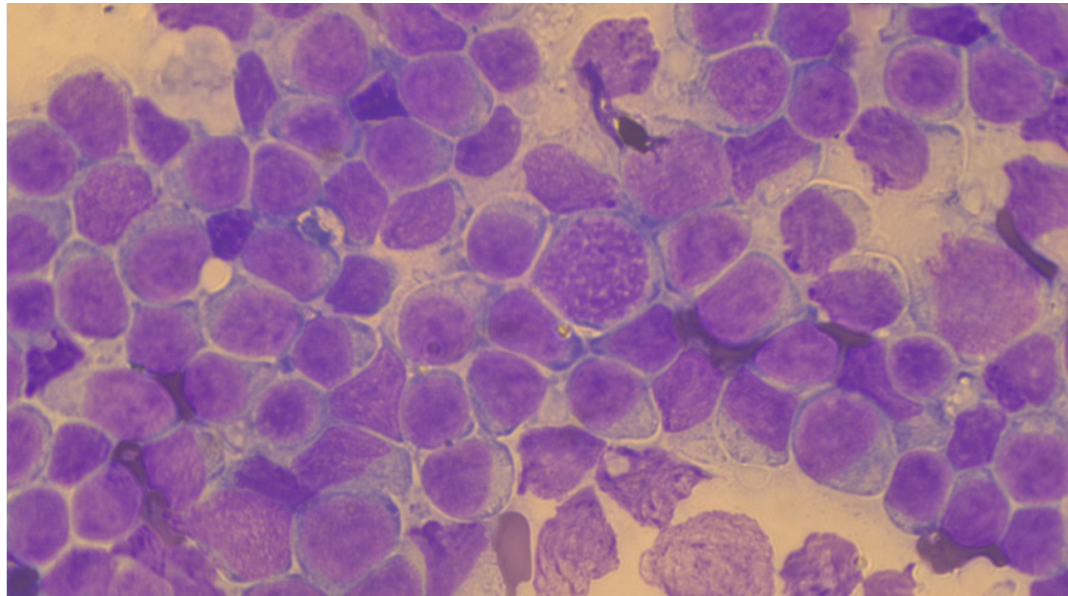


Image shows a field of lymphoid cells collected from the submandibular lymph node in Babe. Note the mitotic figure in the center of the image.

The information and recommendations provided are based on the images presented by the referring veterinarian. No evaluation can be communicated regarding pathology that was not visible in the image/video clips provided.

Thank you for this referral. If the clinical or image interpretation does not parallel your findings or if I can be of any further assistance, please contact me.

**L.D. McGill, DVM, Ph.D., DACVP**  
8288 Top of the World Drive  
Cottonwood Heights, UT 84121  
ldmcgill.vetpath@gmail.com  
cell: 801-865-1220