



DATE PRESENTING CLINICAL SIGNS

2/15/22

Presented as stray to be evaluated for potential adoption. Had diarrhea. Was treated with convenia and hydrolyzed diet. Has since stopped having diarrhea and is now gaining weight. Abdominal ultrasound suspicious for FIP (submitted to sonopath)

INTERPRETED BY CYTOLOGY SUBMISSION

Kidney

L.D. McGill, DVM,
Ph.D, DACVP

OBSERVATIONS

Kidney: Submitted are 12 images of cells collected from the kidney in Crisp. The cellularity in these images is minimal to mild. There are many cells that are naked nuclei. The more prominent cells are scattered macrophages and neutrophils. I think there are also a few lymphocytes. I was unable to identify any malignant criteria.

PATIENT

Crisp AC Paw

INTERPRETATION OF THE FINDINGS & FURTHER RECOMMENDATIONS

Kidney - Suggestive of pyogranulomatous inflammation

SPECIES

Feline

COMMENTS

Pyogranulomatous inflammation in the kidney of the cat is often caused by feline infectious peritonitis. I usually see even more cells and you were able to demonstrate on these images. Kidneys are often difficult to aspirate but you did get some cells. There are no lesions that suggest sepsis or neoplasia. I did not identify any bacteria. I am not able to confirm the diagnosis of FIP but it is still suspicious with this type of inflammatory response. It may be possible to send these slides out for PCR for feline coronavirus to confirm the diagnosis if that procedure is required. Some of the images are slightly out of focus. Make sure you focus on the camera lens.

BREED

DSH

SEX

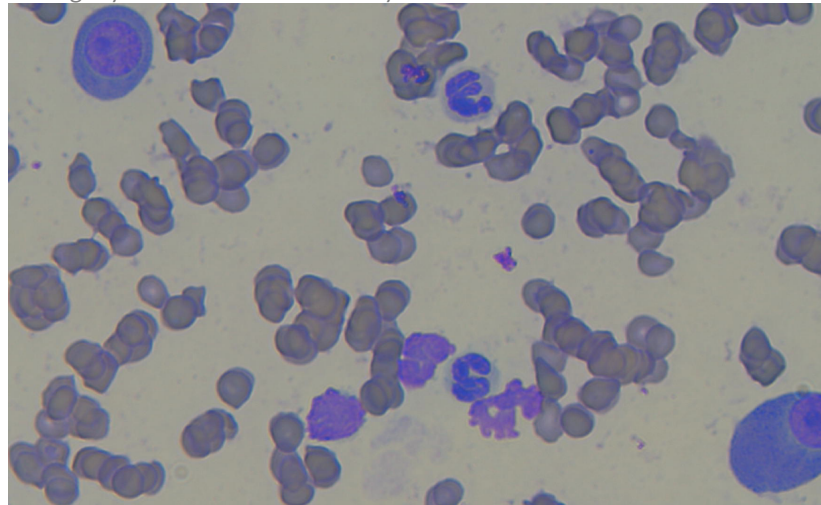
Male

AGE

5

WEIGHT

8.5 lbs



HOSPITAL NAME

Torch Lake Veterinary
Clinic

Image shows some of the inflammatory cells collected from the kidney in Crisp. The larger round cells are macrophages.

REFERRING VET

Dr. Waffle

The information and recommendations provided are based on the images presented by the referring veterinarian. No evaluation can be communicated regarding pathology that was not visible in the image/video clips provided.

Thank you for this referral. If the clinical or image interpretation does not parallel your findings or if I can be of any further assistance please contact me.

INVOICE NUMBER

670



DATE

2/15/22

L.D. McGill, DVM, Ph.D., DACVP
8288 Top of the World Drive
Cottonwood Heights, UT 84121
ldmcgill.vetpath@gmail.com
cell: 801-865-1220

INTERPRETED BY

L.D. McGill, DVM,
Ph.D., DACVP

PATIENT

Crisp AC Paw

SPECIES

Feline

BREED

DSH

SEX

Male

AGE

5

WEIGHT

8.5 lbs

HOSPITAL NAME

Torch Lake Veterinary
Clinic

REFERRING VET

Dr. Waffle

INVOICE NUMBER

670