



DATE PRESENTING CLINICAL SIGNS

2/14/23

History of acute hepatic failure 2016, currently hyperthyroid and diabetic. Losing weight, appetite poor. Recently difficult to regulate diabetes. Palpable abdominal mass.

INTERPRETED BY CYTOLOGY SUBMISSION

L.D. McGill, DVM,
Ph.D, DACVP

Abdominal lymph node

OBSERVATIONS

Abdominal lymph node: Submitted are 4 excellent videos of very good collections of cells from the abdominal lymph node mass in Kona. The cellularity consists of large numbers of round cells. Many of these round cells are large lymphoid cells. There are scattered small lymphocytes and neutrophils but the majority of the cells are large lymphoid cells with prominent nuclei and nucleoli. The cytoplasm is minimal. Where present, the cytoplasm is bluish gray.

PATIENT

Kona Damewood

INTERPRETATION OF THE FINDINGS & FURTHER RECOMMENDATIONS

SPECIES Lymph node - Consistent with high-grade lymphoma.

Feline COMMENTS

The cellularity in the collection is most characteristic of an aggressive high-grade lymphoma. Many of the cells are quite large and irregular. Treatment may be beneficial but will require identification of the cell type with immunophenotyping. An unfavorable prognosis is warranted. Degeneration and inflammation are secondary. Other organs are likely involved. With the clinical signs in other organs in this case demonstrating problems, I'm concerned that a long-term prognosis is poor.

BREED

DSH

SEX

Male Neutered

AGE

15y

WEIGHT

11.96 lbs

HOSPITAL NAME

Cottage Grove
Veterinary Clinic

REFERRING VET

Dr. Damewood

INVOICE NUMBER

894

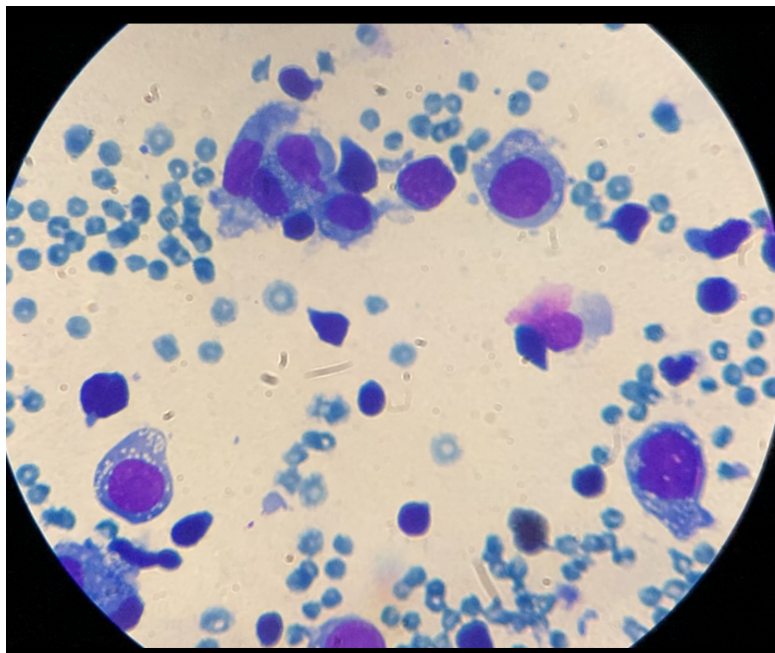


Image shows a representative group of cells collected from the abdominal lymph node in Kona. These cells are showing characteristics of neoplasia.



DATE 2/14/23 The information and recommendations provided are based on the images presented by the referring veterinarian. No evaluation can be communicated regarding pathology that was not visible in the image/video clips provided.

INTERPRETED BY L.D. McGill, DVM, Ph.D., DACVP Thank you for this referral. If the clinical or image interpretation does not parallel your findings or if I can be of any further assistance please contact me.

L.D. McGill, DVM,
Ph.D., DACVP

L.D. McGill, DVM, Ph.D., DACVP
8288 Top of the World Drive
Cottonwood Heights, UT 84121
ldmcgill.vetpath@gmail.com
cell: 801-865-1220

PATIENT

Kona Damewood

SPECIES

Feline

BREED

DSH

SEX

Male Neutered

AGE

15y

WEIGHT

11.96 lbs

HOSPITAL NAME

Cottage Grove
Veterinary Clinic

REFERRING VET

Dr. Damewood

INVOICE NUMBER

894