



DATE PRESENTING CLINICAL SIGNS

2/13/23

Acute onset lymphadenopathy, all peripheral LN are enlarged. Owners report pet has been increasingly lethargic and PU/PD. Ca is high normal, 10.1 mg/dl. Remainder of values are unremarkable..

INTERPRETED BY CYTOLOGY SUBMISSION

L.D. McGill, DVM,
Ph.D, DACVP

Lymph node

OBSERVATIONS

Lymph node: Submitted are a large number of excellent videos and images of cells collected from the lymph node in Axel. The cellularity consists of large numbers of round cells. The majority of round cells are large lymphoid cells with minimal cytoplasm. The nuclei are 2 to 4 to 6 times the size of red blood cells. Nucleoli are prominent and irregular. Mitotic figures were identified. Lymphoglandular structures were identified.

PATIENT

Axel Botkin

INTERPRETATION OF THE FINDINGS & FURTHER RECOMMENDATIONS

SPECIES Lymph node - Consistent with high-grade lymphoma

Canine

COMMENTS

The cellularity is strongly supportive of a high-grade lymphoma. The characteristic large lymphoid cells have prominent nucleoli and are very large. Mitotic figures were identified. If chemotherapy is contemplated, then immunophenotyping of the cells to confirm the specific cell type may be beneficial for prognosis. The slides may be submitted for PARR testing or new slides that are not stained can be submitted for immunocytochemistry staining. Flow cytometry can be beneficial but will require a repeat collection of cells prior to submission to the laboratory. Contacting the laboratory to confirm how to submit flow cytometry samples is encouraged. An unfavorable prognosis is warranted due to the clinical problems in Axel but further therapy certainly may be considered. Consultation with an oncologist is encouraged.

BREED

Doberman

SEX

Male Neutered

AGE

6y

WEIGHT

100 lbs

HOSPITAL NAME

Ruidoso Animal Clinic

REFERRING VET

Dr. Botkin

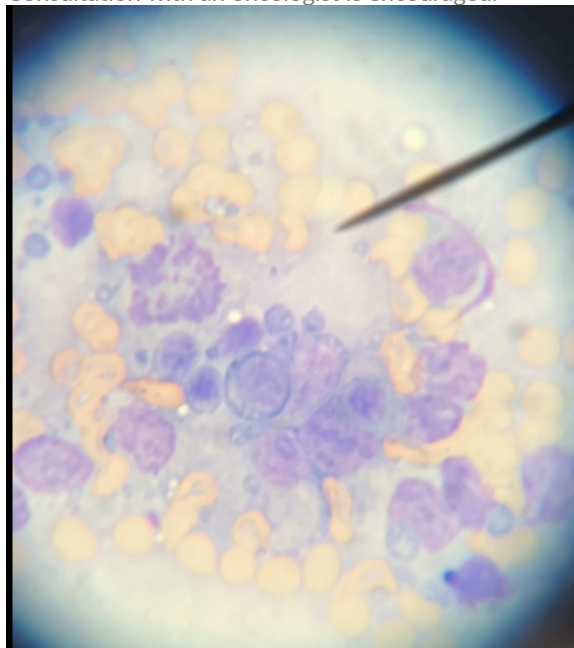


Image shows large lymphoid cells with a mitotic figure. Many cells are smudged in the collection form Axel. There are other fields with even more large cells.

INVOICE NUMBER

892



DATE 2/13/23 The information and recommendations provided are based on the images presented by the referring veterinarian. No evaluation can be communicated regarding pathology that was not visible in the image/video clips provided.

INTERPRETED BY L.D. McGill, DVM, Ph.D., DACVP Thank you for this referral. If the clinical or image interpretation does not parallel your findings or if I can be of any further assistance please contact me.

L.D. McGill, DVM,
Ph.D., DACVP

L.D. McGill, DVM, Ph.D., DACVP
8288 Top of the World Drive
Cottonwood Heights, UT 84121
ldmcgill.vetpath@gmail.com
cell: 801-865-1220

PATIENT

Axel Botkin

SPECIES

Canine

BREED

Doberman

SEX

Male Neutered

AGE

6y

WEIGHT

100 lbs

HOSPITAL NAME

Ruidoso Animal Clinic

REFERRING VET

Dr. Botkin

INVOICE NUMBER

892