



DATE PRESENTING CLINICAL SIGNS

2/11/22

Single cavitated splenic mass FNA; no other lesions noted on ultrasound today. No free fluid is noted today.

INTERPRETED BY

L.D. McGill, DVM,
Ph.D, DACVP

Presented to ER on 12/26 for collapse, small amt free fluid in abd reported; normal thoracic radiographs other than hypovolemia
Labs show mild azotemia with isosthenuria; hyperproteinemia (9.8)with hyperglobulinemia (7.1); CBC mild leukocytosis, low normal HCT

CYTOLOGY SUBMISSION

PATIENT

FNA of single cavitated splenic mass

Foxy Trattner

OBSERVATIONS

Sample Spleen: Submitted are 6 excellent videos of cells collected from the spleen in Foxy. The majority of the cells are round cells. Many of the cells are differentiating towards nucleated RBCs but there are large numbers of cells that are differentiating towards plasma cells. The cells are irregular in size and shape and multinucleated are observed. There are scattered neutrophils and lymphocytes throughout the collection.

SPECIES

Canine

BREED

Pointer

INTERPRETATION OF THE FINDINGS & FURTHER RECOMMENDATIONS

Sampl Spleen - Suggestive of plasmacytoma or early multiple myeloma and marked erythropoietic nodule.

SEX

FS

COMMENTS

Sample The large numbers of plasma cells in many fields causes concern about a plasma cell neoplastic process. Further evaluation for that potential would include globulin increases or other potential enzymatic alternatives associated with plasma cell neoplastic processes. Splenectomy may be in order in this instance with a follow-up biopsy to confirm the presence of neoplastic cells.
Continued evaluation of other tissues may be beneficial in suggesting multiple myeloma. A guarded prognosis is warranted.

AGE

12years

WEIGHT

29kg

HOSPITAL NAME

Pacific Crest Mobile Vet

REFERRING VET

Dr. Harvey/Skagit
Animal Clinic

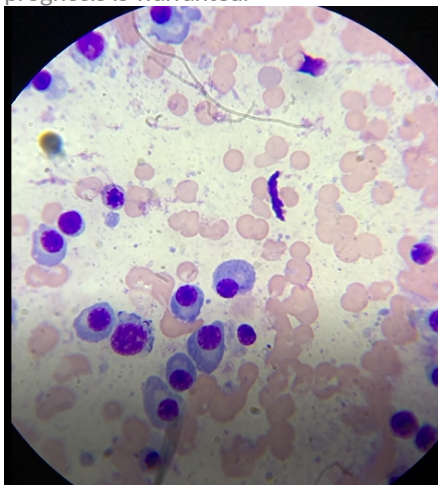


Image shows a field of plasmacytic cells with irregular nuclei collected from Foxy. Other fields had different abnormal plasmacytoid cells.

INVOICE NUMBER

70462



DATE 2/11/22 The information and recommendations provided are based on the images presented by the referring veterinarian. No evaluation can be communicated regarding pathology that was not visible in the image/video clips provided.

INTERPRETED BY Thank you for this referral. If the clinical or image interpretation does not parallel your findings or if I can be of any further assistance please contact me.

L.D. McGill, DVM,
Ph.D, DACVP

L.D. McGill, DVM, Ph.D., DACVP
8288 Top of the World Drive
Cottonwood Heights, UT 84121
ldmcgill.vetpath@gmail.com
cell: 801-865-1220

PATIENT

Foxy Trattner

SPECIES

Canine

BREED

Pointer

SEX

FS

AGE

12years

WEIGHT

29kg

HOSPITAL NAME

Pacific Crest Mobile Vet

REFERRING VET

Dr. Harvey/Skagit
Animal Clinic

INVOICE NUMBER

70462