



**DATE PRESENTING CLINICAL SIGNS**

2/1/23

Increased Appetite with small amount of weight loss. Cat is not handled much and the owners recently noticed a 2x2x2cm lump in the R neck (possibly LN). Lump was hemorrhagic on FNA. Doesn't appear to be painful to the patient but it is firm and fairly immovable. CBC/Chem \*including T4 was WNL on the date of aspiration.

**INTERPRETED BY**

2x2x2cm firm SC mass in the area of R Submandibular LN. CBC/Chem (incl T4) WNL

L.D. McGill, DVM,  
Ph.D, DACVP

**CYTOLOGY SUBMISSION**

Right neck mass

**OBSERVATIONS**

**PATIENT**

Skylar Crandall

Right neck mass: Submitted are 6 videos of collections of cells from the right neck mass on Skylar. The cellularity in 2 of the videos demonstrates large numbers of round cells that in many instances are packeted. These cells have minimal cytoplasm to slight bluish cytoplasm. The nuclei are rounded to elongated. In some areas of the videos they are smudged. There are some cells that suggest lymphoid cells but most of the cells have prominent nucleoli. Other cells do not. There is minimal inflammation which is most prominent in four of the videos.

**SPECIES**

Feline

**INTERPRETATION OF THE FINDINGS & FURTHER RECOMMENDATIONS**

Right neck mass - Round the cell proliferation suggesting lymphoma or possible thyroid carcinoma

**BREED**

Domestic Shorthair

**COMMENTS**

The cellularity in this proliferation supports a proliferative process which in some areas suggests lymphoid cells. The cellularity however is not specific. With some of the aggregation and irregular cellularity, I'm concerned about the possibility of a carcinoma and particularly the possibility of a thyroid carcinoma. Further evaluation of the cells suggests inflammation and hemorrhage. Thyroid carcinomas will result in hemorrhage during aspiration. Excision of the mass and follow up biopsies will be required but at this point I am concerned about thyroid carcinoma or possible lymphoma. A guarded prognosis is warranted.

**SEX**

Female Spayed

**AGE**

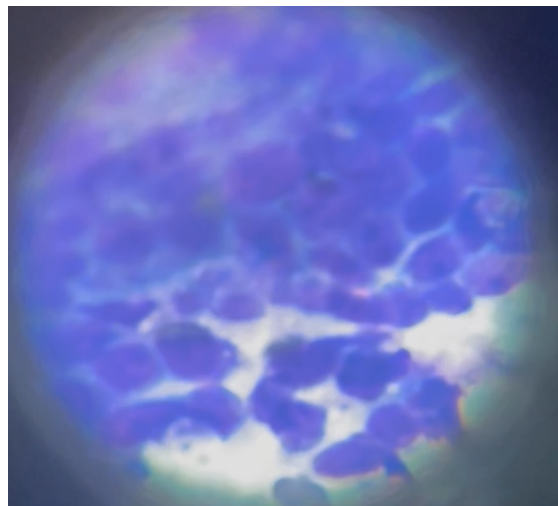
13y

**WEIGHT**

6

**HOSPITAL NAME**

Green Mountain  
Veterinary Hospital



**REFERRING VET**

Dr. Treat

Image shows a representative group of irregular rounded cells collected from Skylar. Note the minimal cytoplasm.

The information and recommendations provided are based on the images presented by the referring veterinarian. No evaluation can be communicated regarding pathology that was not visible in the image/video clips provided.

**INVOICE NUMBER**

885



**DATE**

2/1/23

Thank you for this referral. If the clinical or image interpretation does not parallel your findings or if I can be of any further assistance please contact me.

**INTERPRETED BY**

L.D. McGill, DVM,  
Ph.D, DACVP

**L.D. McGill, DVM, Ph.D., DACVP**  
8288 Top of the World Drive  
Cottonwood Heights, UT 84121  
ldmcgill.vetpath@gmail.com  
cell: 801-865-1220

**PATIENT**

Skylar Crandall

**SPECIES**

Feline

**BREED**

Domestic Shorthair

**SEX**

Female Spayed

**AGE**

13y

**WEIGHT**

6

**HOSPITAL NAME**

Green Mountain  
Veterinary Hospital

**REFERRING VET**

Dr. Treat

**INVOICE NUMBER**

885