



**DATE PRESENTING CLINICAL SIGNS**

12/8/21

Apparent healthy cat on long term Amitriptyline for behavioral wetting  
Routine blood work showed elevated ALT (660) and AST (220)  
Abd. U/S report from Sonopath indicated Increased Portal Markings in liver and some lobar biliary calculi. The spleen was considered "plump"

**INTERPRETED BY**

L.D. McGill, DVM,  
Ph.D, DACVP

**CYTOLOGY SUBMISSION**

Liver

**OBSERVATIONS**

**PATIENT**

MR Hines

Liver: Submitted are 9 excellent videos of minimal to moderate collections of hepatocytes with scattered inflammatory cells and some round cells collected from the liver in MR Hines. Hepatocytes are identified in many fields. These cells have slight vacuolization and granularity of the cytoplasm but there are not large lipid vacuoles. There are scattered lymphocytes and neutrophils in the surrounding red blood cells and associated with hepatocytes. Malignant criteria are not identified in any of the videos.

**SPECIES**

Feline

**INTERPRETATION OF THE FINDINGS & FURTHER RECOMMENDATIONS**

Liver - Mild hepatocellular vacuolization and granularity with increased numbers of small mature lymphocytes.

**BREED**

DSH

**COMMENTS**

The changes in this liver suggest metabolic liver changes which are secondary to other problems. This very likely could be secondary to pancreatitis or enteritis. Some of the ultrasound changes and cellular changes are consistent with lymphocytic cholangiohepatitis. I would be concerned about that condition in MR Hines. I was unable to identify malignant characteristics. There is no suggestion of sepsis. If problems continue, further treatment for pancreatitis or enteritis and treatment for chronic lymphocytic cholangiohepatitis is encouraged. I suspect that the hepatocytes are responding secondarily.

**SEX**

Male Neutered

**AGE**

10y

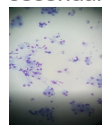


Image shows hepatocytes with vacuolization collected from MR Hines. There are scattered neutrophils and small lymphocytes.

**WEIGHT**

10 lbs

The information and recommendations provided are based on the images presented by the referring veterinarian. No evaluation can be communicated regarding pathology that was not visible in the image/video clips provided.

**HOSPITAL NAME**

Franklin Animal Clinic

Thank you for this referral. If the clinical or image interpretation does not parallel your findings or if I can be of any further assistance please contact me.

**REFERRING VET**

Dr. Doverspike

L.D. McGill, DVM, Ph.D., DACVP  
8288 Top of the World Drive  
Cottonwood Heights, UT 84121  
ldmcgill.vetpath@gmail.com  
cell: 801-865-1220

**INVOICE NUMBER**

639



**DATE**

12/8/21

**INTERPRETED BY**

L.D. McGill, DVM,  
Ph.D, DACVP

**PATIENT**

MR Hines

**SPECIES**

Feline

**BREED**

DSH

**SEX**

Male Neutered

**AGE**

10y

**WEIGHT**

10 lbs

**HOSPITAL NAME**

Franklin Animal Clinic

**REFERRING VET**

Dr. Doverspike

**INVOICE NUMBER**

639