



**DATE PRESENTING CLINICAL SIGNS**

12/5/22

Two week history of enlarged L mandibular LN. Seems painful to the touch  
Enlarged L mandibular LN, no further peripheral lymphadenopathy. Severe periodontal disease

**INTERPRETED BY**

L.D. McGill, DVM,  
Ph.D, DACVP

**CYTOLOGY SUBMISSION**

FNA of Lymph node

**PATIENT**

Sassy Hoffman

**OBSERVATIONS**

Lymph node: Submitted are 2 videos and a large number of images collected from the lymph node in Sassy. The cellularity consists mainly of red blood cells with the scattering of nucleated cells. The nucleated cells are mixed. There are large numbers of small mature lymphocytes. Neutrophils and macrophages are identified. Malignant characteristics are not identified.

**SPECIES**

Canine

**INTERPRETATION OF THE FINDINGS & FURTHER RECOMMENDATIONS**

Lymph node - Chronic separately lymph at night is with reactive restimulated lymph node

**BREED**

Dachshund

**COMMENTS**

**SEX**

FS

The cellularity is a mixed collection with evidence of chronic inflammation. There is no suggestion of malignancy in this collection. This supports inflammation draining from some location over the head or neck region. This easily could be from the nasal or sinus region. Continued evaluation to identify a source of inflammation draining to the lymph node is encouraged. Treatment with anti-inflammatory products or antibiotics may be beneficial.

**AGE**

15y

**WEIGHT**

11.7lb

**HOSPITAL NAME**

Ruidoso Animal Clinic

**REFERRING VET**

Dr. Sarah Botkin

**INVOICE NUMBER**

40656



**DATE**

12/5/22

**INTERPRETED BY**

L.D. McGill, DVM,  
Ph.D., DACVP

**PATIENT**

Sassy Hoffman

**SPECIES**

Canine

**BREED**

Dachshund

**SEX**

FS

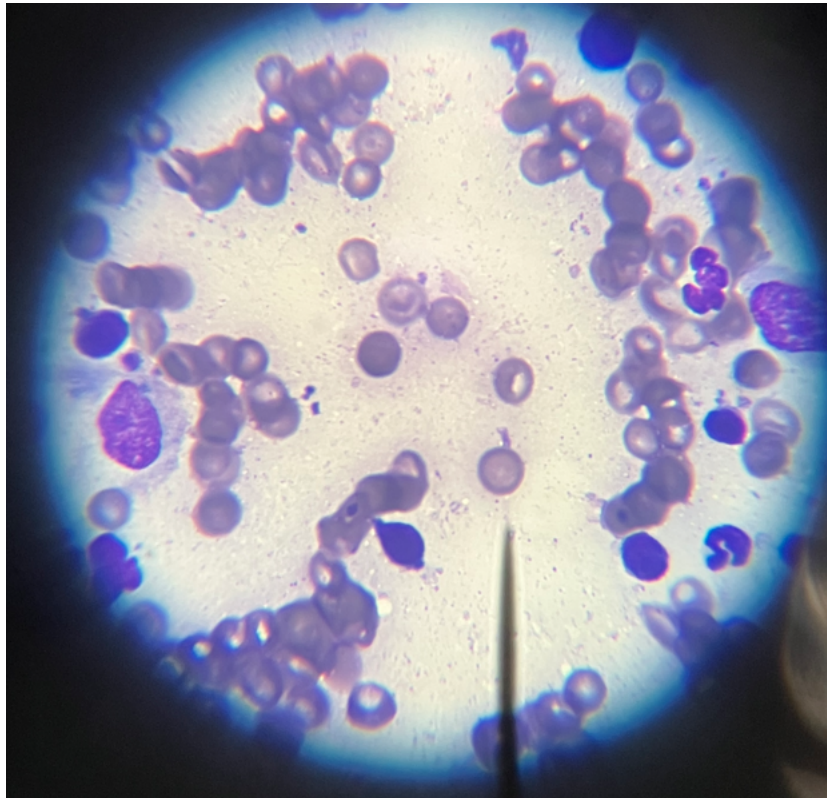


Image shows the RBCs, small lymphocytes, neutrophils and macrophages collected from Sassy. This is the approximate cellularity of most fields of this aspirate.

**AGE**

15y

The information and recommendations provided are based on the images presented by the referring veterinarian. No evaluation can be communicated regarding pathology that was not visible in the image/video clips provided.

**WEIGHT**

11.7lb

Thank you for this referral. If the clinical or image interpretation does not parallel your findings or if I can be of any further assistance, please contact me.

**HOSPITAL NAME**

Ruidoso Animal Clinic

L.D. McGill, DVM, Ph.D., DACVP  
8288 Top of the World Drive  
Cottonwood Heights, UT 84121  
ldmcgill.vetpath@gmail.com  
cell: 801-865-1220

**REFERRING VET**

Dr. Sarah Botkin

**INVOICE NUMBER**

40656