



DATE PRESENTING CLINICAL SIGNS

12/5/22

Seen by rDVM for routine vaccinations; Not having any problems at all. On exam a mid abdominal mass was felt.

Labs: WNL

Rads: Symmetrical Round Mid Abdomina Mass

INTERPRETED BY

U/S (Pending SonoPath): Large, heterogenous, non cavitated splenic mass (9x9cm). No obvious metastatic lesions present.

L.D. McGill, DVM,
Ph.D, DACVP

PATIENT CYTOLOGY SUBMISSION

Mukki Mallory

FNA of Spleen

SPECIES OBSERVATIONS

Canine

Spleen: Submitted are a large number of excellent images of cells collected from the spleen in Mukki. The cellularity consists of large numbers of round cells which are lymphocytes. There are scattered large lymphocytes, but many are small to intermediate in size. Atypical lymphoid cells are hard to identify. This appears to be a lymphoid collection from the spleen.

BREED

Lab X

INTERPRETATION OF THE FINDINGS & FURTHER RECOMMENDATIONS

SEX

Spleen - Large numbers of lymphocytes consistent with lymphoid nodular hyperplasia of the spleen.

Male Neutered

COMMENTS

AGE

11y

The cellularity is a good collection of lymphocytes. There are large early lymphocytes scattered throughout. They have prominent nucleoli. These cells are not the predominant cellularity and thus I suspect a reactive lymphoid nodule. This is very likely secondary to some type of chronic inflammation in the abdominal cavity. The source could be the intestine, pancreas or other locations. A guarded prognosis is warranted since the underlying source has not been confirmed.

WEIGHT

115lbs

HOSPITAL NAME

Franklin Animal Clinic
Inc.

REFERRING VET

Dr. Sam Doverspike

INVOICE NUMBER

40655



DATE

12/5/22

INTERPRETED BY

L.D. McGill, DVM,
Ph.D, DACVP

PATIENT

Mukki Mallory

SPECIES

Canine

BREED

Lab X

SEX

Male Neutered

AGE

11y

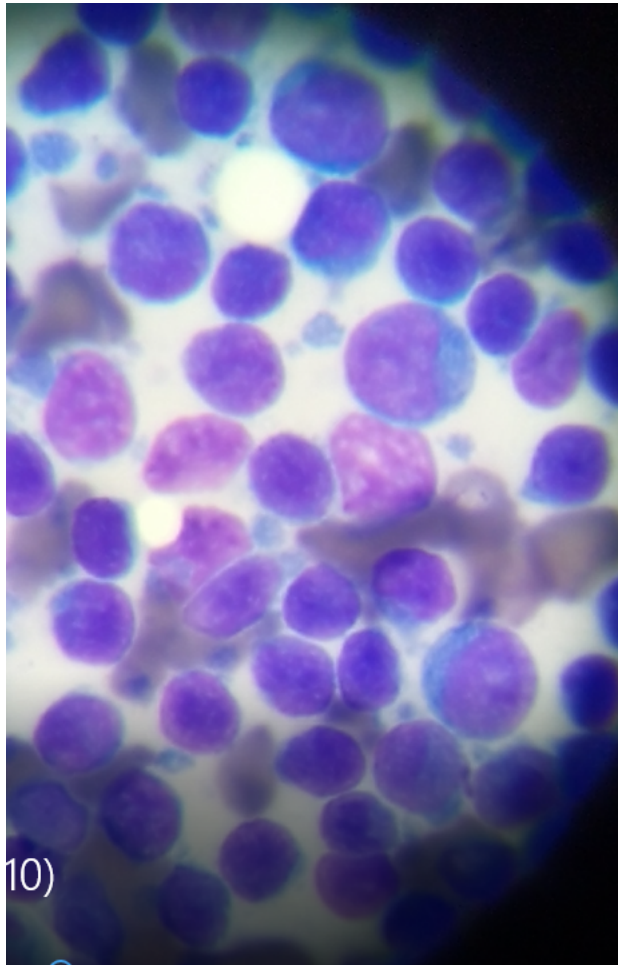


Image shows a group of lymphocytes collected from the spleen in Mukki. Note the 2 or 3 large cells with prominent nucleoli but they have not effaced the cellularity.

WEIGHT

115lbs

The information and recommendations provided are based on the images presented by the referring veterinarian. No evaluation can be communicated regarding pathology that was not visible in the image/video clips provided.

HOSPITAL NAME

Franklin Animal Clinic
Inc.

Thank you for this referral. If the clinical or image interpretation does not parallel your findings or if I can be of any further assistance, please contact me.

REFERRING VET

Dr. Sam Doverspike

L.D. McGill, DVM, Ph.D., DACVP
8288 Top of the World Drive
Cottonwood Heights, UT 84121
ldmcgill.vetpath@gmail.com
cell: 801-865-1220

INVOICE NUMBER

40655



DATE

12/5/22

INTERPRETED BY

L.D. McGill, DVM,
Ph.D, DACVP

PATIENT

Mukki Mallory

SPECIES

Canine

BREED

Lab X

SEX

Male Neutered

AGE

11y

WEIGHT

115lbs

HOSPITAL NAME

Franklin Animal Clinic
Inc.

REFERRING VET

Dr. Sam Doverspike

INVOICE NUMBER

40655