



**DATE PRESENTING CLINICAL SIGNS**

12/31/21 Prostate FNA

**CYTOLOGY SUBMISSION**

Prostate

**INTERPRETED BY**

L.D. McGill, DVM,  
Ph.D., DACVP

**OBSERVATIONS**

Submitted are 3 excellent videos of moderate to excellent collections of cells from the prostatic region in Eiji. The cellularity consists of large numbers of epithelial cells that are packeted in solid to irregular patterns. There are scattered aggregates of erythrocytes with some inflammatory cells. The epithelial cells demonstrate distinct cytoplasm and irregular nuclei. There is prominent anisocytosis and anisokaryosis in the cells.

**PATIENT**

Eiji Baxter

**INTERPRETATION OF THE FINDINGS & FURTHER RECOMMENDATIONS**

Prostate - Consistent with urothelial carcinoma of the prostatic urethra.

**SPECIES COMMENTS**

Canine

The cellularity in this collection strongly supports a carcinoma and is most likely a urothelial carcinoma of the prostatic urethra. The cells do not support prostatic cells but there most are consistent with those of urothelial cells proliferating irregularly. Degeneration and inflammation is occurring secondarily. Treatment for urothelial cell carcinoma is encouraged. Excision may be beneficial. An unfavorable prognosis is warranted in my opinion.

**BREED**

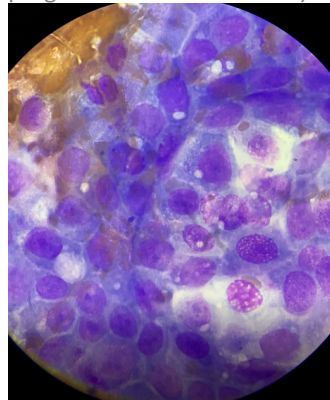
Mastiff

**SEX**

Male Neutered

**AGE**

11y



**WEIGHT**

140 lbs

Image shows neoplastic epithelial cells with anisocytosis and anisokaryosis collected from the prostate region in Eiji.

**HOSPITAL NAME**

Reid Veterinary Hospital

The information and recommendations provided are based on the images presented by the referring veterinarian. No evaluation can be communicated regarding pathology that was not visible in the image/video clips provided.

Thank you for this referral. If the clinical or image interpretation does not parallel your findings or if I can be of any further assistance please contact me.

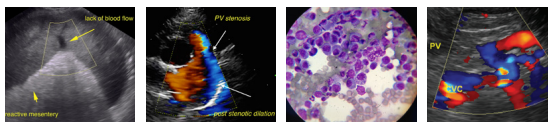
**REFERRING VET**

Dr. Reid

L.D. McGill, DVM, Ph.D., DACVP  
8288 Top of the World Drive  
Cottonwood Heights, UT 84121  
ldmcgill.vetpath@gmail.com  
cell: 801-865-1220

**INVOICE NUMBER**

651



**DATE**

12/31/21

**INTERPRETED BY**

L.D. McGill, DVM,  
Ph.D, DACVP

**PATIENT**

Eiji Baxter

**SPECIES**

Canine

**BREED**

Mastiff

**SEX**

Male Neutered

**AGE**

11y

**WEIGHT**

140 lbs

**HOSPITAL NAME**

Reid Veterinary Hospital

**REFERRING VET**

Dr. Reid

**INVOICE NUMBER**

651