



**DATE** 12/31/2021  
**PRESENTING CLINICAL SIGNS** Hx of mast cell. Ultrasound showed iliac lymphadenopathy, mildly heterogenous spleen, irregular left kidney. FNA done on iliac LN, R/O round cell vs other.

**INTERPRETED BY** L.D. McGill, DVM, Ph.D, DACVP  
**CYTOLOGY SUBMISSION** U/S-guided FNA of iliac lymph node.

**PATIENT** Igor Barrales  
**OBSERVATIONS** Lymph node: Submitted are 5 excellent videos of cells collected from the internal iliac lymph node in Igor. The cellularity consists of large numbers of round cells. The round cells have prominent cytoplasm with round nuclei. Some of these cells have granular material in their cytoplasm. The granular material is metachromatic. There are aggregates of eosinophils in the collection with very few inflammatory cells. Very few lymphocytes are identified.

**SPECIES** Canine  
**INTERPRETATION OF THE FINDINGS & FURTHER RECOMMENDATIONS** Lymph node - Metastatic mast cell tumor suggesting high-grade.

**BREED** Doberman Pinscher  
**COMMENTS** The cellularity strongly supports an aggressive mast cell tumor with minimal granularity. The cells are poorly differentiated. They are prominent throughout all of the videos. Degeneration and inflammation are secondary but minimal. This cellularity is likely metastatic from the primary process. A guarded to unfavorable prognosis is warranted with this aggressive cellularity.

**SEX**

Male neutered

**AGE**

7-year-old

**WEIGHT**

63 lbs

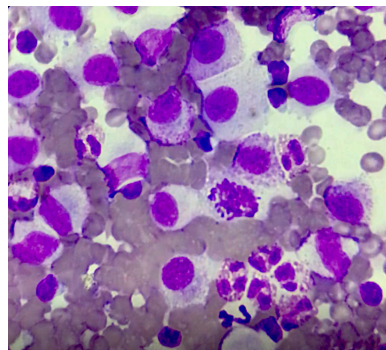


Image above demonstrates large numbers of round cells, many of which have granular cytoplasm in the collection from Igor. There are aggregates of eosinophils in the collection as well.

**HOSPITAL NAME** Rockaway AH  
**The information and recommendations provided are based on the images presented by the referring veterinarian. No evaluation can be communicated regarding pathology that was not visible in the image/video clips provided.**

Thank you for this referral. If the clinical or image interpretation does not parallel your findings or if I can be of any further assistance please contact me.

**REFERRING VET**

Dr. Maniar  
**L.D. McGill, DVM, Ph.D., DACVP**  
8288 Top of the World Drive  
Cottonwood Heights, UT 84121  
ldmcgill.vetpath@gmail.com  
cell: 801-865-1220



**DATE**

12/31/2021

**INTERPRETED BY**

L.D. McGill, DVM,  
Ph.D, DACVP

**PATIENT**

Igor Barrales

**SPECIES**

Canine

**BREED**

Doberman Pinscher

**SEX**

Male neutered

**AGE**

7-year-old

**WEIGHT**

63 lbs

**HOSPITAL NAME**

Rockaway AH

**REFERRING VET**

Dr. Maniar