



DATE PRESENTING CLINICAL SIGNS

12/30/21

Losing weight. AUS-mesenteric LN enlargements

CYTOLOGY SUBMISSION

Lymph node

INTERPRETED BY

L.D. McGill, DVM,
Ph.D., DACVP

OBSERVATIONS

Lymph node: Submitted are 2 excellent videos of minimal cellular collection from the lymph node in Zeus. There are scattered lymphoid cells throughout the smear. Some of the lymphoid cells are degenerate. There are a few large lymphoid cells but many small to intermediate cells. The large cells are less than 40% of the lymphoid cells in the collection. Some of the larger cells have irregular nuclei with multiple nucleoli. All of the cells have minimal bluish gray cytoplasm. Scattered neutrophils are identified.

PATIENT

Zeus Kuehn

INTERPRETATION OF THE FINDINGS & FURTHER RECOMMENDATIONS

Lymph node - Minimal cellularity with a few atypical lymphoid cells and many small to intermediate lymphoid cells.

SPECIES

Canine

COMMENTS

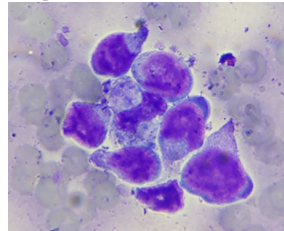
The cellularity is not diagnostic of a specific process. There are some irregular lymphoid cells which could suggest early lymphoma. The complication is that this type of cellular change can also occur in markedly reactive lymphoid tissue. With the minimal cellularity, this is more difficult to confirm. There are a few neutrophils suggesting mild inflammation draining to the node. The cellularity is suspicious but not diagnostic for lymphoma. Lymphoid cells are the only cell type present in the smears. A repeat collection of lymphoid tissue with the goal of collecting more nucleated cells can be considered in further workup of Zeus. A guarded prognosis is still warranted and lymphoma is on the differential diagnostic list.

BREED

Boxer

SEX

Male Neutered



AGE

8y

Image shows a group of large lymphoid cells with irregular nuclei collected from Zeus. These cells are suspicious but there are not enough of them to diagnose lymphoma.

WEIGHT

60

The information and recommendations provided are based on the images presented by the referring veterinarian. No evaluation can be communicated regarding pathology that was not visible in the image/video clips provided.

HOSPITAL NAME

Bayshore Veterinary
Hospital

Thank you for this referral. If the clinical or image interpretation does not parallel your findings or if I can be of any further assistance please contact me.

REFERRING VET

Dr. Hunt

L.D. McGill, DVM, Ph.D., DACVP
8288 Top of the World Drive
Cottonwood Heights, UT 84121
ldmcgill.vetpath@gmail.com
cell: 801-865-1220

INVOICE NUMBER

650



DATE

12/30/21

INTERPRETED BY

L.D. McGill, DVM,
Ph.D, DACVP

PATIENT

Zeus Kuehn

SPECIES

Canine

BREED

Boxer

SEX

Male Neutered

AGE

8y

WEIGHT

60

HOSPITAL NAME

Bayshore Veterinary
Hospital

REFERRING VET

Dr. Hunt

INVOICE NUMBER

650