



**DATE PRESENTING CLINICAL SIGNS**

12/29/21

US showed approx 3 cm pancreatic cyst vs abscess vs neoplasia, regional inflammation. Drainage of hypochoic fluid arfea and FNA of parenchyma

**INTERPRETED BY CYTOLOGY SUBMISSION**

L.D. McGill, DVM,  
Ph.D, DACVP

FNA of Pancreas

**OBSERVATIONS**

**PATIENT**

Rusty Cicotto

Sample Pancreas: Submitted are 9 excellent videos of cells collected from the fluid-filled region in the pancreas from Rusty. The cellularity is consistent throughout all of the videos. There are large numbers of neutrophils interspersed with scattered macrophages and necrotic debris. There are massive numbers of bacteria some of which appear to be coccoid bacteria and others are coccobacilli. The fluid is quite prominent with some protein in the background. There is necrotic debris in the collection.

**SPECIES**

feline

**INTERPRETATION OF THE FINDINGS & FURTHER RECOMMENDATIONS**

Pancreas - Severe suppurative inflammation with bacterial infection.

**BREED**

DSH

**COMMENTS**

The cellularity supports an abscess with severe inflammation as the major process in this fluid collection from the pancreas in Rusty. The cellularity includes massive numbers of neutrophils and some macrophages. Many neutrophils are laden with bacteria. Bacterial culture is definitely in order but I have seen cases similar to this where the bacteria did not grow due to the degeneration of neutrophils and loss of viability in the bacteria. In this instance if the culture is negative, antibiotic therapy is still in order due to the massive numbers of bacteria in these collections. There is no suggestion of malignancy. A guarded prognosis is warranted due to the severe inflammation and bacterial infection.

**SEX**

Male Neutered

**AGE**

14 years

**WEIGHT**

n/a

**HOSPITAL NAME**

Animal Care Centers of  
Flanders

**REFERRING VET**

Dr. Hallihan

**INVOICE NUMBER**

70438



**DATE**

12/29/21

**INTERPRETED BY**

L.D. McGill, DVM,  
Ph.D, DACVP

**PATIENT**

Rusty Cicotto

**SPECIES**

feline

**BREED**

DSH

**SEX**

Male Neutered

**AGE**

14 years

**WEIGHT**

n/a

**HOSPITAL NAME**

Animal Care Centers of  
Flanders

**REFERRING VET**

Dr. Hallihan

**INVOICE NUMBER**

70438

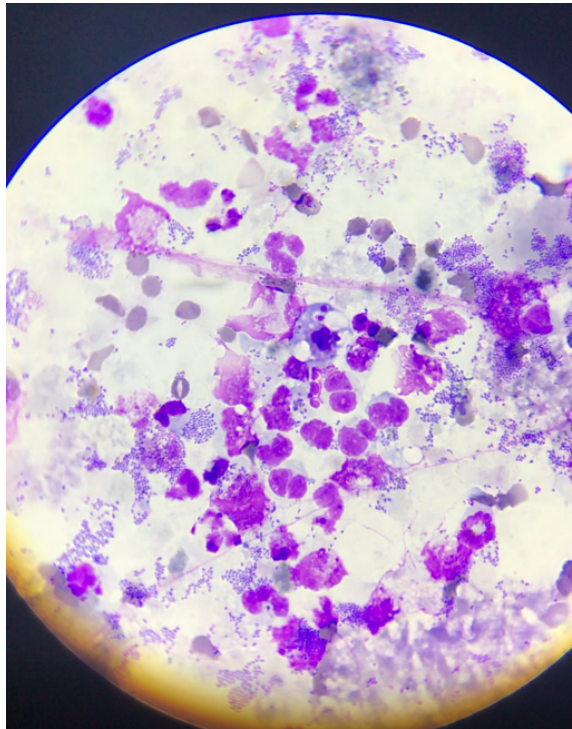


Image shows large numbers of neutrophils many of which are degenerate with a massive background of bacteria collected from Rusty.

The information and recommendations provided are based on the images presented by the referring veterinarian. No evaluation can be communicated regarding pathology that was not visible in the image/video clips provided.

Thank you for this referral. If the clinical or image interpretation does not parallel your findings or if I can be of any further assistance please contact me.

L.D. McGill, DVM, Ph.D., DACVP  
8288 Top of the World Drive  
Cottonwood Heights, UT 84121  
ldmcgill.vetpath@gmail.com  
cell: 801-865-1220