



**DATE PRESENTING CLINICAL SIGNS**

12/26/22

Patient presented for routine exam 12/26/22. Owner noticed mass over left hip/lumbar ~1 month ago. Mass is 1.9x2cm, firm, irregular, subcutaneous. Has projections that grow deeper into tissue and ventrocranially ~2cm.

**INTERPRETED BY CYTOLOGY SUBMISSION**

L.D. McGill, DVM,  
Ph.D, DACVP

Dermal mass

**PATIENT**

Remi Schreiner

**OBSERVATIONS**

Dermal mass: Submitted are 4 excellent videos of very good collections of cells from the dermal mass on Remi. The cellularity is mixed with large numbers of lymphocytes but a very predominant number of macrophages. There are scattered neutrophils in the collection. The macrophages have a vacuolated to slightly granulated cytoplasm. All of them are very active. The lymphoid cells are mainly small to intermediate with a few irregular lymphoid cells present. Malignant characteristics are not prominent.

**SPECIES INTERPRETATION OF THE FINDINGS & FURTHER RECOMMENDATIONS**

Feline

Dermal mass - Pyogranulomatous and lymphocytic collection

**BREED**

DSH

**SEX**

Male Neutered

**COMMENTS**

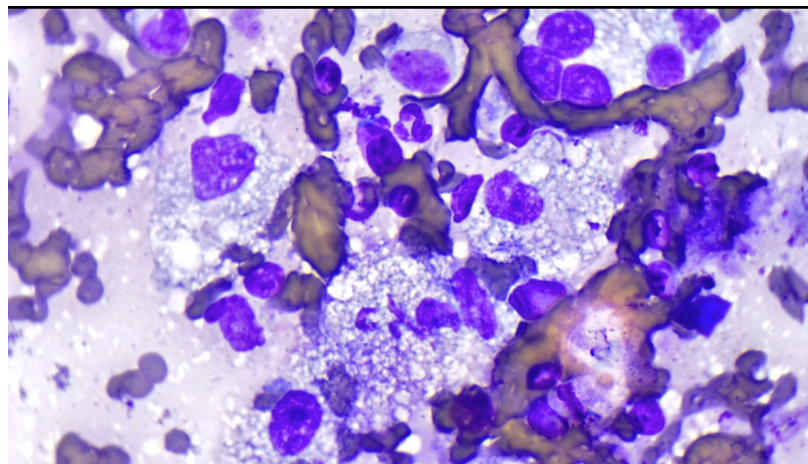
The cellularity includes large numbers of lymphoid cells some of which appear to be slightly atypical. There are large numbers of prominent macrophages throughout the collection. The vacuolization in the macrophages suggests that they are phagocytosing lipid or possibly some unusual bacterial material. Occasionally Mycobacterial organisms will demonstrate this pattern in macrophages in skin lesions. Feline cutaneous leprosy and lymphoma are concerns that I have with this collection. The most likely process is chronic inflammation with degeneration of fat and inflammation with a marked lymphocytic response. An unusual injection site granuloma could cause this type of reaction. Malignancy is not confirmed but cannot be completely ruled out. A guarded prognosis is warranted and thus a follow-up excision and biopsy is encouraged.

**AGE**

9y

**WEIGHT**

12#



**HOSPITAL NAME**

Rotterdam Veterinary  
Hospital

Image shows macrophages with a foamy cytoplasm surrounded by neutrophils and lymphocytes collected from Remi. The uniformity of the vacuoles suggests a consistent size structure.

**REFERRING VET**

Dr. Scarpinato

The information and recommendations provided are based on the images presented by the referring veterinarian. No evaluation can be communicated regarding pathology that was not visible in the image/video clips provided.

**INVOICE NUMBER**

869



**DATE** Thank you for this referral. If the clinical or image interpretation does not parallel your findings or if I can be of any further assistance please contact me.

12/26/22

**INTERPRETED BY** L.D. McGill, DVM, Ph.D., DACVP  
8288 Top of the World Drive  
Cottonwood Heights, UT 84121  
ldmcgill.vetpath@gmail.com  
cell: 801-865-1220

**PATIENT**

Remi Schreiner

**SPECIES**

Feline

**BREED**

DSH

**SEX**

Male Neutered

**AGE**

9y

**WEIGHT**

12#

**HOSPITAL NAME**

Rotterdam Veterinary  
Hospital

**REFERRING VET**

Dr. Scarpinato

**INVOICE NUMBER**

869