

DATE PRESENTING CLINICAL SIGNS

12/24/22

Straining to defecate, vomiting, anorexia. Mass effect pushing down colon and bladder on rads.

INTERPRETED BY CYTOLOGY SUBMISSION

U/S Guided FNA: Iliac LN mass

L.D. McGill, DVM,
Ph.D, DACVP

OBSERVATIONS

Iliac Lymph Node: Submitted are 4 excellent videos of moderate to excellent collections of cells from the iliac lymph node in Maizy. The cellularity consists mainly of round cells. The majority of the round cells are small lymphocytes. Scattered throughout are large lymphoid cells, rare macrophages and neutrophils. Some of the large lymphoid cells show pleomorphic nuclei that appear to be lobulated. There are others suggestive of early mitotic figures. Lymphocytes with lobulated nuclei are observed in several fields.

PATIENT

Maizy Berrand

SPECIES

Feline

INTERPRETATION OF THE FINDINGS & FURTHER RECOMMENDATIONS

Iliac lymph node - Suggestive of lymphoma and possible Hodgkins-like lymphoma.

BREED COMMENTS

DSH

The lobulated lymphocyte nuclei suggest Hodgkins-like lymphoma which has been reported in the cat. There is inflammation but it appears to be secondary. Confirmation of this diagnosis will require further testing such as PARR or follow up biopsy. An unfavorable prognosis is warranted. Many of the lymphocytes are small but there are adequate atypical cells to suggest this diagnosis.

SEX

FS

AGE

7yrs

WEIGHT

9.9#

HOSPITAL NAME

Newton Veterinary
Hospital

REFERRING VET

Dr. Kim

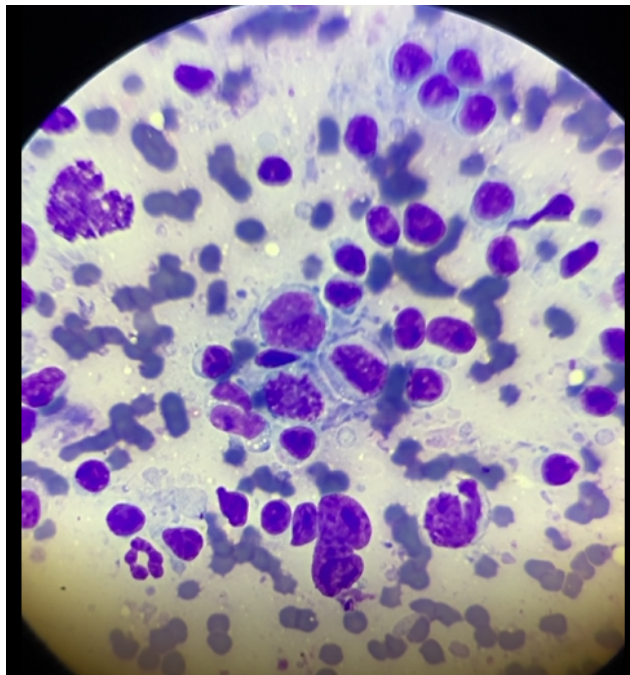
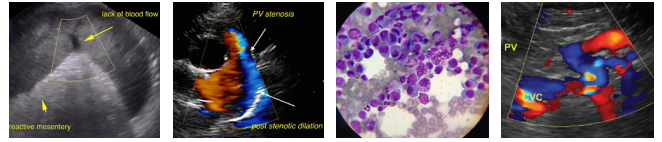


Image shows some large lymphocytes with a couple of potential mitotic figures and lobulated nuclei in the lymphoid cells collected from Maizy. Many of the lymphocytes are small to intermediate.

INVOICE NUMBER

9098



DATE

12/24/22

INTERPRETED BY

L.D. McGill, DVM,
Ph.D., DACVP

The information and recommendations provided are based on the images presented by the referring veterinarian. No evaluation can be communicated regarding pathology that was not visible in the image/video clips provided.

Thank you for this referral. If the clinical or image interpretation does not parallel your findings or if I can be of any further assistance please contact me.

PATIENT

Maizy Berrand

L.D. McGill, DVM, Ph.D., DACVP
8288 Top of the World Drive
Cottonwood Heights, UT 84121
ldmcgill.vetpath@gmail.com
cell: 801-865-1220

SPECIES

Feline

BREED

DSH

SEX

FS

AGE

7yrs

WEIGHT

9.9#

HOSPITAL NAME

Newton Veterinary
Hospital

REFERRING VET

Dr. Kim

INVOICE NUMBER

9098