



DATE PRESENTING CLINICAL SIGNS

12/24/21 Not doing well, anorexic
PE: hyphema/uveitis OS, palpably enlarged and irregular kidneys bilaterally.
BUN 64, Creat 3.6, WBC ct 4.4k FIV +
AUS: bilateral severe, nodular renomegaly with subcapsular halo. Possible mass in liver as well.

INTERPRETED BY

L.D. McGill, DVM,
Ph.D, DACVP

CYTOLOGY SUBMISSION

FNA of Kidney

OBSERVATIONS

Kidney: Submitted are 8 excellent videos of cells collected from the kidney in Hunter. The cellularity is excellent with large numbers of round cells in all of the fields. There are scattered neutrophils and rare macrophages. There are rare small mature lymphocytes but the majority of the cells are large irregular lymphoid cells with minimal cytoplasm and there are many with prominent nucleoli. Degenerate debris is present.

SPECIES

Feline

INTERPRETATION OF THE FINDINGS & FURTHER RECOMMENDATIONS

Kidney - High-grade lymphoma

COMMENTS

The cellularity is classical for a high-grade lymphoma in the kidney in the cat. Immunophenotyping of the cells can be applied to these slides but immunophenotyping is not as beneficial in the cat with respect to prognosis as it is in the dog. An unfavorable prognosis is warranted. Chemotherapy can be attempted. With the FIV positive nature of this patient, there also could be FELV in some hidden location as well.

SEX

Male Neutered

AGE

9y

WEIGHT

12.8 lbs

HOSPITAL NAME

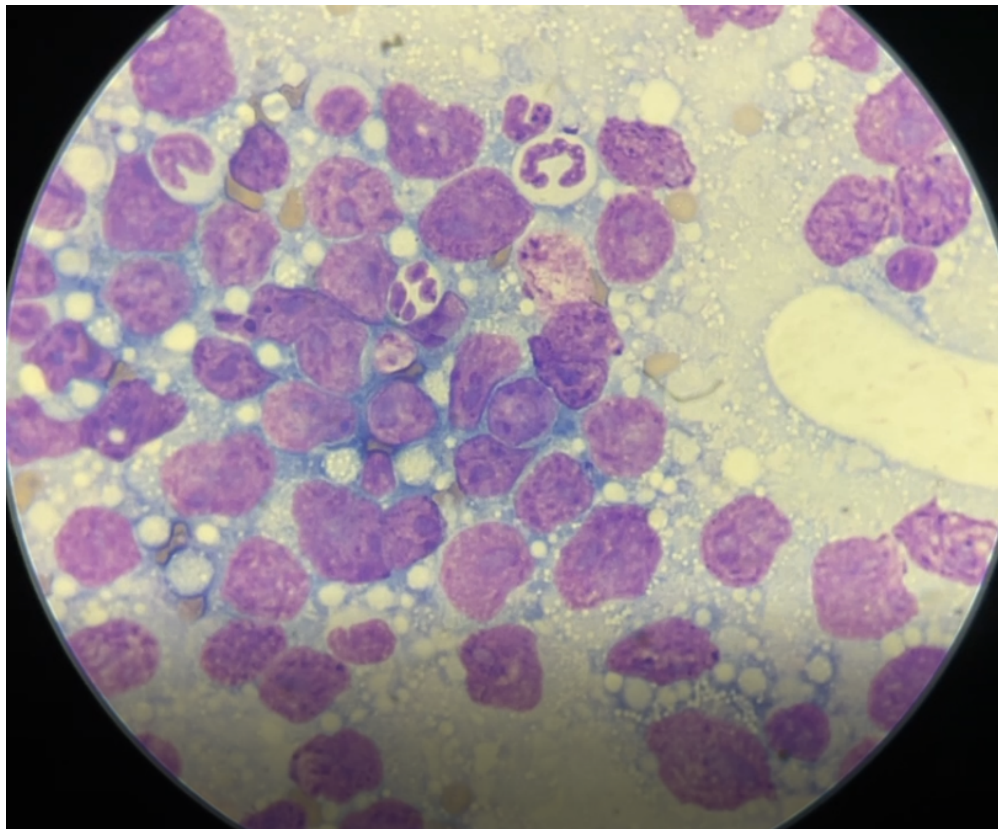
Scanvet

REFERRING VET

Dr. Lane/Dr. Sanders

INVOICE NUMBER

70434





DATE 12/24/21
Image shows a representative group of cells collected from Hunter. Compare the large irregular lymphoid nuclei (many with nucleoli) to the neutrophils and small lymphocytes present.

INTERPRETED BY L.D. McGill, DVM, Ph.D, DACVP
The information and recommendations provided are based on the images presented by the referring veterinarian. No evaluation can be communicated regarding pathology that was not visible in the image/video clips provided.

Thank you for this referral. If the clinical or image interpretation does not parallel your findings or if I can be of any further assistance please contact me.

PATIENT
Hunter Cote
L.D. McGill, DVM, Ph.D., DACVP
8288 Top of the World Drive
Cottonwood Heights, UT 84121
ldmcgill.vetpath@gmail.com
cell: 801-865-1220

SPECIES
Feline

BREED
DSH

SEX
Male Neutered

AGE
9y

WEIGHT
12.8 lbs

HOSPITAL NAME
Scanvet

REFERRING VET
Dr. Lane/Dr. Sanders

INVOICE NUMBER
70434