



DATE PRESENTING CLINICAL SIGNS

12/23/22

Abdominal Ultrasound performed. Hypoechoic, 3cm mass found on abdominal wall adjacent to liver.

INTERPRETED BY

L.D. McGill, DVM,
Ph.D, DACVP

CYTOLOGY SUBMISSION

FNA of Abdominal mass

PATIENT

Smokey Scolaro

OBSERVATIONS

Abdominal mass: Submitted are 5 excellent videos of minimal to moderate nucleated cellular collections and necrotic debris from the abdominal mass in Smokey. There are moderate numbers of neutrophils in many fields with very few numbers in others. Much of the tissue is coagulated blood and necrotic debris. There are scattered spindloid cells and scattered macrophages in the collection. Malignant characteristics are not identified.

SPECIES

Canine

INTERPRETATION OF THE FINDINGS & FURTHER RECOMMENDATIONS

Abdominal mass - Necrotic and hemorrhagic inflammatory mass

BREED

peke

SEX

Male Neutered

COMMENTS

The cellularity supports an inflammatory necrotic process with hemorrhage and inflammation. The inflammation is mainly neutrophilic. There are reactive spindloid cells and macrophages. There are no changes that would support neoplasia in this collection, but this does not rule neoplasia out completely. My suspicion is that this is a necrotic traumatic process either as a result of trauma from external sources or possibly a ruptured organ in this region. Exploratory may be required to confirm the extent and type of process.

AGE

15y

WEIGHT

16

HOSPITAL NAME

Rotterdam Veterinary
Hospital

REFERRING VET

Dr. Anna St. Sir

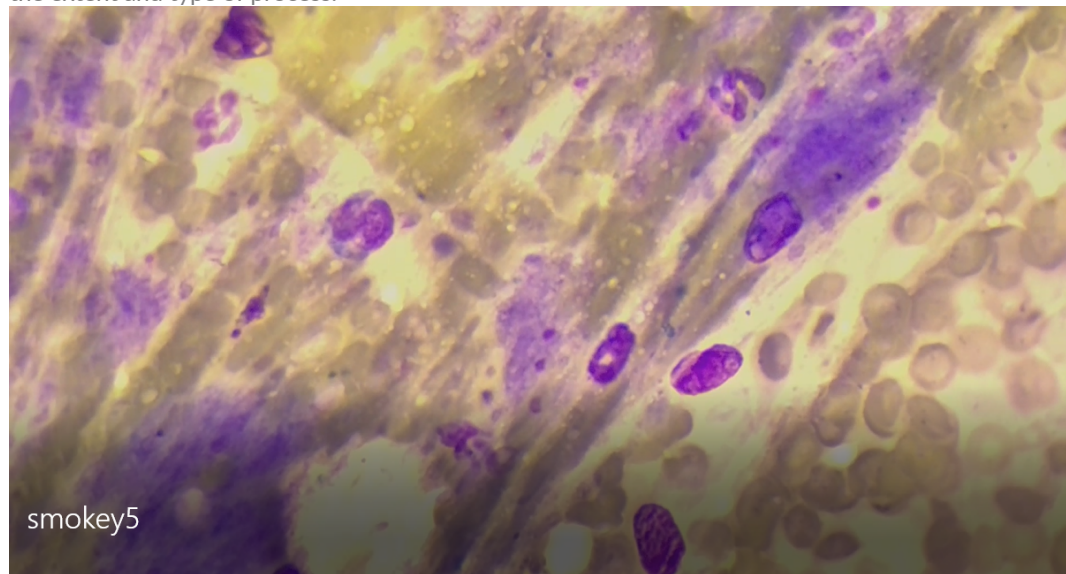


Image shows a representative field of cells, hemorrhage and necrosis in the collection from Smokey. Most of the field is hemorrhage and necrotic debris.

INVOICE NUMBER

40625



DATE 12/23/22 The information and recommendations provided are based on the images presented by the referring veterinarian. No evaluation can be communicated regarding pathology that was not visible in the image/video clips provided.

INTERPRETED BY L.D. McGill, DVM, Ph.D., DACVP Thank you for this referral. If the clinical or image interpretation does not parallel your findings or if I can be of any further assistance, please contact me.

L.D. McGill, DVM,
Ph.D., DACVP

L.D. McGill, DVM, Ph.D., DACVP
8288 Top of the World Drive
Cottonwood Heights, UT 84121
ldmcgill.vetpath@gmail.com
cell: 801-865-1220

PATIENT
Smokey Scolaro

SPECIES
Canine

BREED
peke

SEX
Male Neutered

AGE
15y

WEIGHT
16

HOSPITAL NAME
Rotterdam Veterinary
Hospital

REFERRING VET
Dr. Anna St. Sir

INVOICE NUMBER
40625