



DATE PRESENTING CLINICAL SIGNS

12/22/21

Previously the cat was brought to another practice wherein an oral pain killer (generic not mentioned by the owner) and the owner was advised to give the medication at home. Yesterday night the cat was presented as emergency because the he vomitted clotted blood and he was in pain on the abdomen.

INTERPRETED BY

L.D. McGill, DVM,
Ph.D, DACVP

Blood test, X-ray and US were performed. On the ultrasound, it was noted that there is free fluid accumulation anterior to the urinary bladder, hyperechoic fat tissue is also. The stomach has hyperechoic structure attached on its wall and the rugae appears thickened. Ex lap was performed, yellow to brownish fluid was present in the abdominal cavity and the adipose tissues are inflame. One perforation was found on the greater curvature of the stomach. Another ulcer was seen near the perforation. The damaged tissues of the stomach are removed and the hole is closed.

PATIENT

Stark Al Shamsi

WBC 24.72(5.5-19.5) Neutro 16.33(2.5-14) HCT 11.66(24-45) RBC 4.44(5-10) BUN 33 (10-30) ALT 15 (20-100)

CYTOLOGY SUBMISSION

Abdominal fluid

SPECIES

Feline

OBSERVATIONS

Abdominal fluid: Submitted are several images of cells collected from the abdominal fluid in Stark. The cells are almost all neutrophils with scattered erythrocytes. There may be one or two macrophages but they are few in number. There is a protein background throughout. There are no changes to support malignancy.

BREED

Persian

INTERPRETATION OF THE FINDINGS & FURTHER RECOMMENDATIONS

Abdominal fluid - Mild suppurative peritonitis

SEX

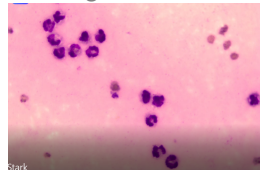
Male

COMMENTS

The changes in this collection are those of a mild inflammatory process which is likely leaking from the ulcerated regions of the stomach. There is no suggestion of malignancy nor sepsis. There are changes that support suppurative inflammation. The hemorrhage and protein are likely secondary to the bleeding from the ulcerated process.

AGE

4 y 7 mo



WEIGHT

4.7 kgs

Image shows neutrophils and RBCs with a background of protein collected from the abdominal fluid in Stark.

The information and recommendations provided are based on the images presented by the referring veterinarian. No evaluation can be communicated regarding pathology that was not visible in the image/video clips provided.

HOSPITAL NAME

City Veterinary Clinic

Thank you for this referral. If the clinical or image interpretation does not parallel your findings or if I can be of any further assistance please contact me.

REFERRING VET

Dr. dela Cruz

L.D. McGill, DVM, Ph.D., DACVP

8288 Top of the World Drive
Cottonwood Heights, UT 84121

INVOICE NUMBER

648

ldmcgill.vetpath@gmail.com
cell: 801-865-1220



DATE

12/22/21

INTERPRETED BY

L.D. McGill, DVM,
Ph.D, DACVP

PATIENT

Stark Al Shamsi

SPECIES

Feline

BREED

Persian

SEX

Male

AGE

4 y 7 mo

WEIGHT

4.7 kgs

HOSPITAL NAME

City Veterinary Clinic

REFERRING VET

Dr. dela Cruz

INVOICE NUMBER

648