



**DATE PRESENTING CLINICAL SIGNS**

12/20/22

Weight loss of 2 lbs in the past 4 months. Vomiting daily for 2 weeks. PU/PD.  
PE: dehydrated, T-98.5, QAR, BCS 3/9 with muscle wasting.  
AUS: enlarged mesenteric LN (largest 3.5cm x 1.3cm) with maintained shape and echotexture. L kidney mildly enlarged. Thickened SI walls, with normal layering.  
CBC: WBC 26k, Neut 22.8k, Eos 780. Hct 35%.  
Chem: ALT 120, BUN 35, Creat 1.2. A:G ratio 0.7  
UA SG 1.038

**INTERPRETED BY**

L.D. McGill, DVM,  
Ph.D, DACVP

**CYTOLOGY SUBMISSION**

Lymph node

**PATIENT**

Spike Toftner

**OBSERVATIONS**

Lymph node: Submitted are 8 excellent videos of cells collected from the lymph node in Spike. The cellularity consists of large numbers of lymphocytes the majority of which are small mature lymphocytes. Scattered reactive lymphoid cells are identified. There are scattered neutrophils and macrophages in the collection. The cellularity is mixed with inflammation strongly suggested from the neutrophils and macrophages.

**SPECIES**

Feline

**INTERPRETATION OF THE FINDINGS & FURTHER RECOMMENDATIONS**

Lymph node - Pyogranulomatous lymphadenitis with reactive or stimulated lymphoid tissue

**BREED**

DSH

**COMMENTS**

There is evidence of chronic inflammation in these lymph nodes. This includes neutrophils and macrophages. This is most suggestive of feline coronavirus infection. Lymphoid tissue is markedly stimulated. There are some fields that cause concern about early lymphoma with the inflammation and other changes, feline coronavirus seems to be the most likely diagnosis. Lymphoid tissue is markedly reactive. Continued evaluation for feline coronavirus and PARR testing is encouraged.

**SEX**

Male Neutered

**AGE**

12y

**WEIGHT**

7.4 lbs

**HOSPITAL NAME**

Scanvet

**REFERRING VET**

Dr. Sheridan

**INVOICE NUMBER**

865

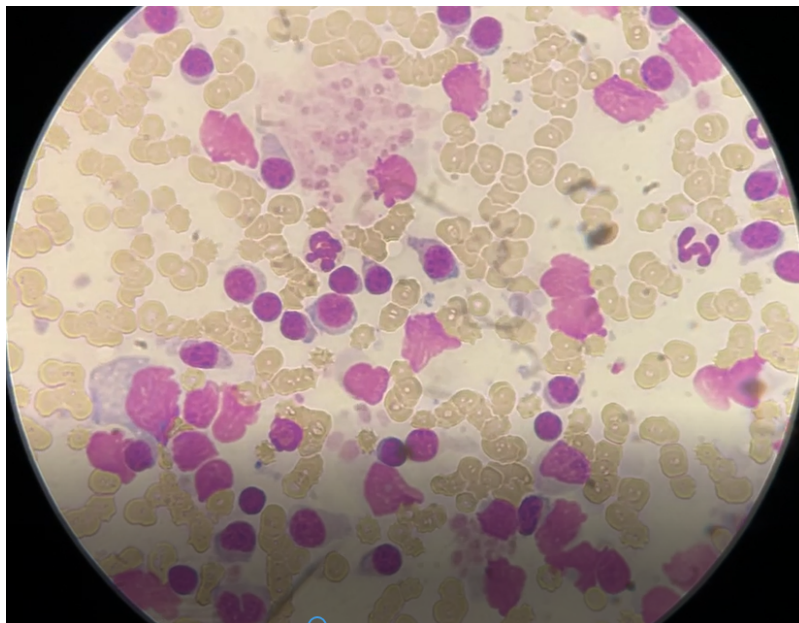


Image shows neutrophils and macrophages interspersed in the lymphoid cells from Spike. There is a clump of platelets.



**DATE**

12/20/22

The information and recommendations provided are based on the images presented by the referring veterinarian. No evaluation can be communicated regarding pathology that was not visible in the image/video clips provided.

**INTERPRETED BY**

L.D. McGill, DVM,  
Ph.D., DACVP

Thank you for this referral. If the clinical or image interpretation does not parallel your findings or if I can be of any further assistance please contact me.

**PATIENT**

Spike Toftner

L.D. McGill, DVM, Ph.D., DACVP  
8288 Top of the World Drive  
Cottonwood Heights, UT 84121  
ldmcgill.vetpath@gmail.com  
cell: 801-865-1220

**SPECIES**

Feline

**BREED**

DSH

**SEX**

Male Neutered

**AGE**

12y

**WEIGHT**

7.4 lbs

**HOSPITAL NAME**

Scanvet

**REFERRING VET**

Dr. Sheridan

**INVOICE NUMBER**

865