



DATE PRESENTING CLINICAL SIGNS

12/20/22
Nodular omental changes and free fluid
R/O carcinomatosis/lymphomatosis
Pleural effusion

INTERPRETED BY

L.D. McGill, DVM,
Ph.D, DACVP

CYTOLOGY SUBMISSION

FNA of Cytospin Effusion

PATIENT

Oliver Goodwin

OBSERVATIONS

Pleural fluid: Submitted are a large number of images of concentrated cells from the pleural fluid in Oliver. The cellularity is mixed. There are large numbers of polymorphonuclear cells and many of these cells appear to be eosinophils. There are scattered round cells and prominent reactive mesothelial cells. The cells have vacuoles in their cytoplasm, and some demonstrate pseudopodia. Malignant characteristics are not identified in these cells.

SPECIES

Canine

BREED

labrador

INTERPRETATION OF THE FINDINGS & FURTHER RECOMMENDATIONS

Pleural fluid - Chronic suppurative and eosinophilic inflammation with prominent reactive mesothelial cells and macrophages.

SEX

Male Neutered

COMMENTS

Sample The cellularity in this collection is more characteristic of an inflammatory process than neoplastic process. The inflammation appears to be eosinophilic suggesting allergy or possibly parasitic problems in the pleural cavity. Further evaluation of the lung may be beneficial in identifying an underlying process. A bacterial infection cannot be ruled out completely. A guarded prognosis is warranted since the underlying process is not identified.

AGE

8

WEIGHT

68

HOSPITAL NAME

Torch Lake Veterinary
Clinic

REFERRING VET

Dr. Adrienne Waffle

INVOICE NUMBER

60624



DATE

12/20/22

INTERPRETED BY

L.D. McGill, DVM,
Ph.D, DACVP

PATIENT

Oliver Goodwin

SPECIES

Canine

BREED

labrador

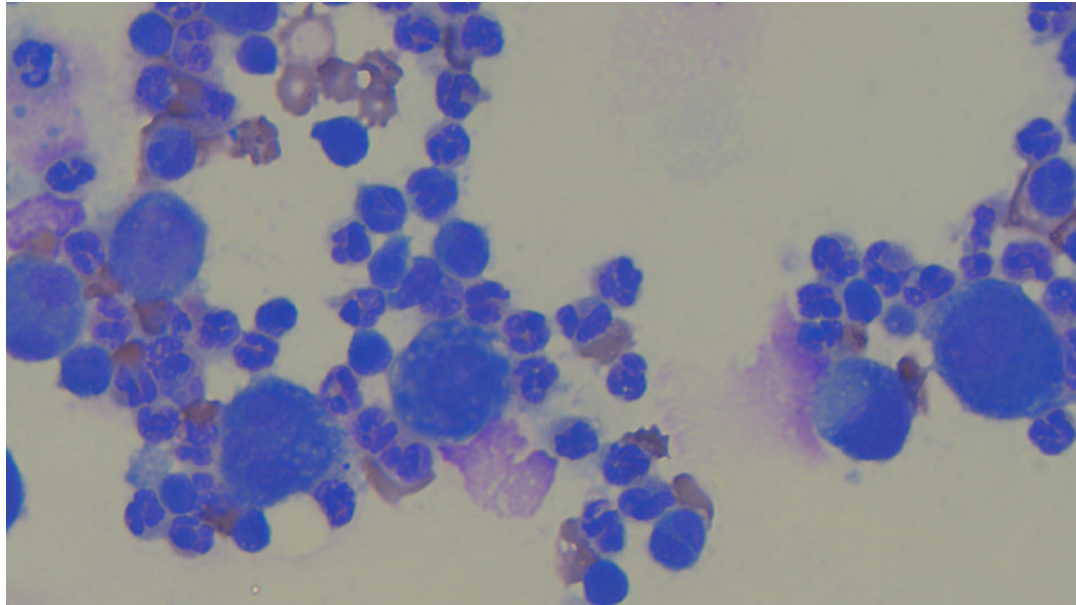


Image shows a representative collection of cells from the pleural fluid in Oliver. The majority of the cells are neutrophils and eosinophils. Large cells are macrophages.

SEX

Male Neutered

The information and recommendations provided are based on the images presented by the referring veterinarian. No evaluation can be communicated regarding pathology that was not visible in the image/video clips provided.

AGE

8

Thank you for this referral. If the clinical or image interpretation does not parallel your findings or if I can be of any further assistance, please contact me.

WEIGHT

68

L.D. McGill, DVM, Ph.D., DACVP
8288 Top of the World Drive
Cottonwood Heights, UT 84121
ldmcgill.vetpath@gmail.com
cell: 801-865-1220

HOSPITAL NAME

Torch Lake Veterinary
Clinic

REFERRING VET

Dr. Adrienne Waffle

INVOICE NUMBER

60624