

**DATE PRESENTING CLINICAL SIGNS**

12/20/22

The owner noticed some mass on the chin. Louie is eating less these days and has also lost some weight. A circular, ulcerated nodule of about 5-6cm in circumference was noticed on the chin. It bled fairly during FNA. Furthert diagnostics such as blood test were declined by the owner. The cat was about 6-7% dehydrated on presentation. The cat had lost about 500g of weight

**INTERPRETED BY**

L.D. McGill, DVM,  
Ph.D, DACVP

**CYTOLOGY SUBMISSION**

FNA of Dermal

**PATIENT**

Louie Joanna

**OBSERVATIONS**

**SPECIES**

Feline

Chin mass: Submitted are 2 excellent videos of very good collections of cells from the chin mass on Louie Joanna. The cellularity consists of a consistent group of cells that have rounded to slightly elongated nuclei. The cells appear to be elongated. Occasionally they demonstrate chain-like patterns. They are aggregated irregularly. There are structures that suggest pigment in some of the cells. This could be melanin.

**BREED**

Persian cross

**INTERPRETATION OF THE FINDINGS & FURTHER RECOMMENDATIONS**

Chin mass - Epithelial cell proliferation suggestive of basal cell tumor.

**SEX**

Male

**COMMENTS**

The cellularity has a benign pattern, but chain-like patterns are common with basal cell tumor. These growths have also been named trichoepithelioma. They have a benign pattern and benign growth. Excision of these growths is expected to result in a favorable prognosis. Metastasis is not common. Margins do not have to be wide. Complete excision however is recommended.

**AGE**

15 years

**WEIGHT**

4.64 kg

**HOSPITAL NAME**

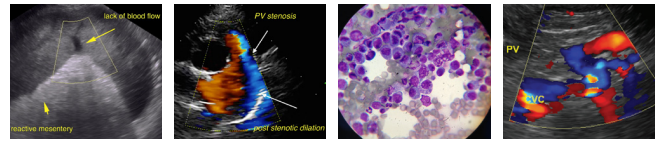
City veterinary clinic,  
Abu Dhabi, Khalifa City

**REFERRING VET**

Dr. Inam ul haq DVM  
MRCVS

**INVOICE NUMBER**

40662



**DATE**

12/20/22

**INTERPRETED BY**

L.D. McGill, DVM,  
Ph.D, DACVP

**PATIENT**

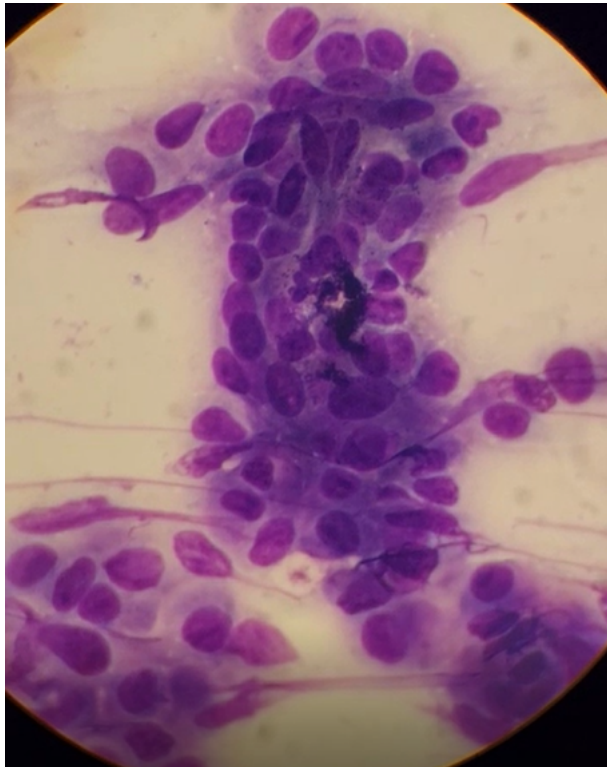
Louie Joanna

**SPECIES**

Feline

**BREED**

Persian cross



**SEX**

Image shows a representative group of cells with a chain-like pattern and aggregation. There may be some pigment present.

Male

**AGE**

The information and recommendations provided are based on the images presented by the referring veterinarian. No evaluation can be communicated regarding pathology that was not visible in the image/video clips provided.

15 years

Thank you for this referral. If the clinical or image interpretation does not parallel your findings or if I can be of any further assistance, please contact me.

**WEIGHT**

4.64 kg

**L.D. McGill, DVM, Ph.D., DACVP**  
8288 Top of the World Drive  
Cottonwood Heights, UT 84121  
ldmcgill.vetpath@gmail.com  
cell: 801-865-1220

**HOSPITAL NAME**

City veterinary clinic,  
Abu Dhabi, Khalifa City

**REFERRING VET**

Dr. Inam ul haq DVM  
MRCVS

**INVOICE NUMBER**

40662