



DATE PRESENTING CLINICAL SIGNS

12/19/22

Pet was seen for frequent vomiting, has history of Cushing's disease. On abdominal ultrasound - 2 cm hypoechoic nodule in the spleen with expansion of capsule. Prostate is slightly enlarged with mineralized center, bilaterally enlarged adrenal glands. Sample from splenic nodule was taken.

INTERPRETED BY CYTOLOGY SUBMISSION

Spleen

L.D. McGill, DVM,
Ph.D, DACVP

OBSERVATIONS

Spleen: Submitted are 6 excellent videos of very good collections of cells from the spleen in Rocco. The cellularity is consistent throughout all of the videos. The cells are all small lymphocytes. The small lymphocytes have nuclei that are approximately the size of red blood cells. They have minimal cytoplasm. Atypical lymphoid cells are not identified. Smudge nuclear debris is identified in a few of these cells. Nucleoli are not identified.

PATIENT

Rocco Boulette

INTERPRETATION OF THE FINDINGS & FURTHER RECOMMENDATIONS

SPECIES Spleen - Mature lymphoid collection consistent with lymphoid nodular hyperplasia.

Canine

COMMENTS

The cellularity in this collection is strongly supportive of a lymphoid nodular hyperplasia within the spleen. It is not characteristic of lymphoma in the videos that we have. These are excellent videos. The lymphocytes are small and structured in the normal manner. Lymphoid nodular hyperplasia is a common lesion in the spleen and it is commonly secondary to other problems. I suspect that there are other organs with pathology in the abdominal cavity. This could be in the pancreas or in the intestine or even the prostate. A guarded prognosis is warranted since we do not know the underlying process.

BREED

Shitzu

SEX

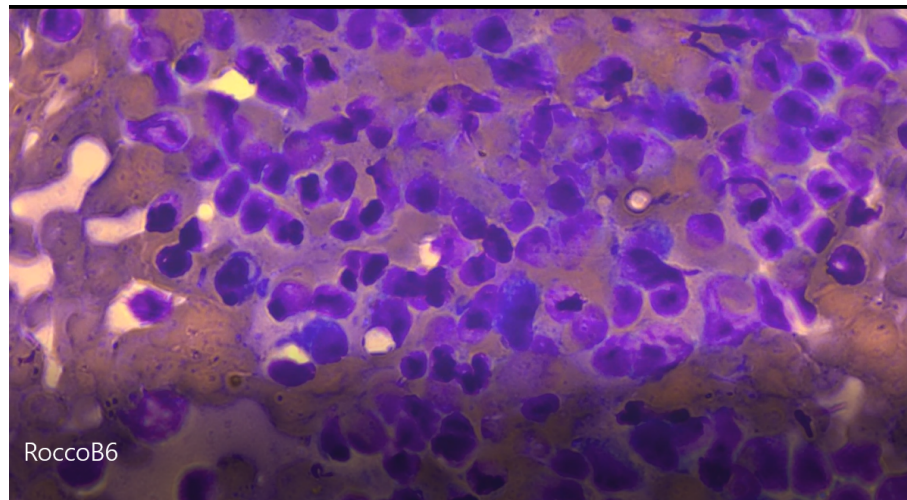
Male Neutered

AGE

15y

WEIGHT

16 lbs



RoccoB6

HOSPITAL NAME

Central Veterinary
Hospital

Image shows a group of small lymphocytes collected from the spleen in Rocco. The nuclei are the approximate size of RBCs.

REFERRING VET

Dr. St. Sir

The information and recommendations provided are based on the images presented by the referring veterinarian. No evaluation can be communicated regarding pathology that was not visible in the image/video clips provided.

Thank you for this referral. If the clinical or image interpretation does not parallel your findings or if I can be of any further assistance please contact me.

INVOICE NUMBER

862



DATE

12/19/22 **L.D. McGill, DVM, Ph.D., DACVP**
8288 Top of the World Drive
Cottonwood Heights, UT 84121
ldmcgill.vetpath@gmail.com
cell: 801-865-1220

INTERPRETED BY

L.D. McGill, DVM,
Ph.D, DACVP

PATIENT

Rocco Boulette

SPECIES

Canine

BREED

Shitzu

SEX

Male Neutered

AGE

15y

WEIGHT

16 lbs

HOSPITAL NAME

Central Veterinary
Hospital

REFERRING VET

Dr. St. Sir

INVOICE NUMBER

862