



DATE PRESENTING CLINICAL SIGNS

12/17/22

Mass on left inguinal area, increase in size from marble to golf ball in past month. Well adhered to inguinal ring area. 2.5 x 2.5 x 2.5 cm

INTERPRETED BY

L.D. McGill, DVM,
Ph.D, DACVP

CYTOLOGY SUBMISSION

Inguinal mass

OBSERVATIONS

Inguinal mass: Submitted are 5 excellent videos of cells collected from the inguinal mass on Toto. The cellularity consists of irregular polyhedral to slightly elongated cells. There is prominent anisokaryosis with scattered cells showing cytoplasm. There are rare inflammatory cells including neutrophils and macrophages. Specific other cells are not identified. There is some eosinophilic amorphous material in the smears.

PATIENT

Toto Kolb

INTERPRETATION OF THE FINDINGS & FURTHER RECOMMENDATIONS

Inguinal mass - Neoplastic process suggestive of a sarcoma such as a myxofibrosarcoma.

SPECIES

Canine

COMMENTS

This is definitely a malignant process when evaluating the nuclei. I suspect a sarcoma such as a myxofibrosarcoma or possibly an osteosarcoma. Other neoplastic processes may be considered but the cellularity is limited. Wide excision of the mass is suggested with a followup biopsy. This should help to identify the source and confirm therapy for Toto. An outside possibility is a mass invading through the inguinal ring. A guarded to unfavorable prognosis is warranted.

BREED

Cairn Terrier

SEX

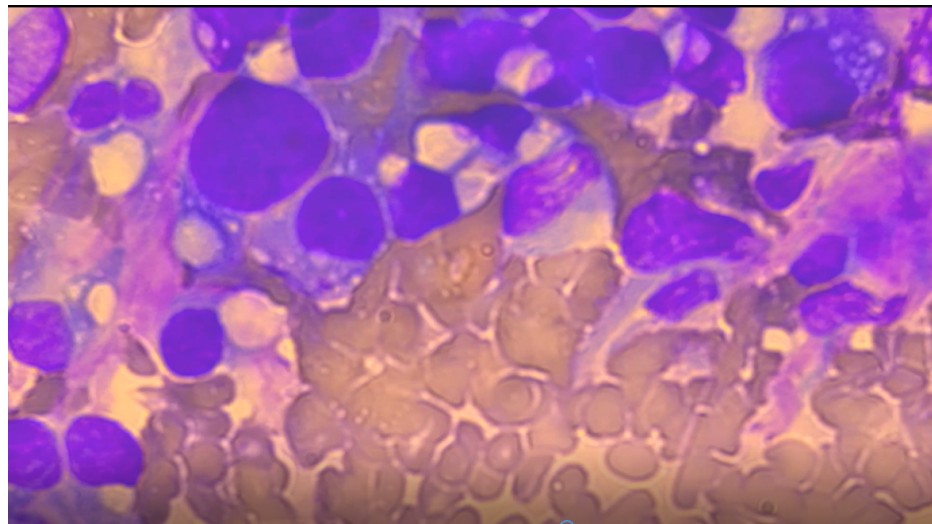
Male Neutered

AGE

14y

WEIGHT

20 lbs



HOSPITAL NAME

Central Veterinary
Hospital

Image shows marked anisokaryosis and anisocytosis in these cells collected from Toto. Notice the pink amorphous material in the background.

REFERRING VET

Dr. Hardaker

The information and recommendations provided are based on the images presented by the referring veterinarian. No evaluation can be communicated regarding pathology that was not visible in the image/video clips provided.

Thank you for this referral. If the clinical or image interpretation does not parallel your findings or if I can be of any further assistance please contact me.

INVOICE NUMBER

860



DATE

12/17/22

L.D. McGill, DVM, Ph.D., DACVP
8288 Top of the World Drive
Cottonwood Heights, UT 84121
ldmcgill.vetpath@gmail.com
cell: 801-865-1220

INTERPRETED BY

L.D. McGill, DVM,
Ph.D., DACVP

PATIENT

Toto Kolb

SPECIES

Canine

BREED

Cairn Terrier

SEX

Male Neutered

AGE

14y

WEIGHT

20 lbs

HOSPITAL NAME

Central Veterinary
Hospital

REFERRING VET

Dr. Hardaker

INVOICE NUMBER

860