



DATE PRESENTING CLINICAL SIGNS

12/17/21 4-6 week history of swelling along R medial thigh. Swelling waxes and wanes. Mild RH lameness
Firm swelling R medial thigh. U/s shows a poorly defined intramuscular mass. FNA, cytology consistent with MCT disease. Teletology to confirm prior to oncology consult.

INTERPRETED BY CYTOLOGY SUBMISSION

Right thigh swelling

L.D. McGill, DVM,
Ph.D, DACVP

OBSERVATIONS

Right thigh swelling: Submitted are 3 very good videos and 6 images of cells collected from the right thigh swelling on Henry. The cellularity is characteristic with large numbers of purple to metachromatic granules in some cells and many free granules in the surrounding tissue. Some of the cells are poorly granulated. The nuclei are large and slightly irregular. There are scattered polymorphonuclear cells in the collection.

PATIENT

Henry Ridge

INTERPRETATION OF THE FINDINGS & FURTHER RECOMMENDATIONS

Right thigh swelling - Mast cell tumor

SPECIES

Canine

COMMENTS

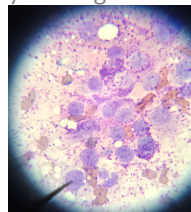
The cellularity is characteristic of a mast cell tumor. This growth is at least a grade 2 mast cell tumor but could be grade 3 to high-grade. A guarded prognosis is warranted with this mass. Evaluation of regional and distal lymph nodes would be encouraged. This tumor process has been known to metastasize distally as well as proximally. With this excellent cellular collection, I am able to confirm your diagnosis of mast cell tumor.

BREED

Pug

SEX

Male Neutered



AGE

2.5 yo

Image shows tumor mast cells with irregular granularity. Note the free granules. There is a polymorphonuclear cell in the lower center.

WEIGHT

25 lbs

The information and recommendations provided are based on the images presented by the referring veterinarian. No evaluation can be communicated regarding pathology that was not visible in the image/video clips provided.

Thank you for this referral. If the clinical or image interpretation does not parallel your findings or if I can be of any further assistance please contact me.

HOSPITAL NAME

Ruidoso Animal Clinic

L.D. McGill, DVM, Ph.D., DACVP

8288 Top of the World Drive
Cottonwood Heights, UT 84121
ldmcgill.vetpath@gmail.com
cell: 801-865-1220

REFERRING VET

Dr. Botkin

INVOICE NUMBER

644