



DATE PRESENTING CLINICAL SIGNS

12/15/22

Distended abdomen and slow to finish meals. Pericardial tap (blood/hemorrhagic fluid) cytospin.
AUS: moderate to large amount ascites. No other abnormalities noted (masses, etc)
Abd tap: clear fluid.
Echo: pericardial effusion with collapsed R atrium. Possible soft tissue mass attached to R atrium/auricle.

INTERPRETED BY

L.D. McGill, DVM,
Ph.D, DACVP

CYTOLOGY SUBMISSION

Pericardial effusion

OBSERVATIONS

PATIENT Pericardial fluid: Submitted are 7 excellent videos of minimal to moderate collections of cells from the pericardial fluid from Roxie. The majority of the cells are RBCs with scattered neutrophils and reactive mesothelial cells. The mesothelial cells show a foamy, vacuolated cytoplasm. Some of these cells contain RBCs and nuclear debris. Malignant characteristics are not identified.

Roxie Burnsworth

SPECIES INTERPRETATION OF THE FINDINGS & FURTHER RECOMMENDATIONS

Canine

Pericardial fluid - Hemorrhagic and mild suppurative inflammation with reactive mesothelial cells.

COMMENTS

Breed

Bull Terrier Mix

There is prominent evidence of hemorrhage and inflammation in this collection. There are no changes to support neoplasia or sepsis. The most common lesion I have seen in the right auricle is hemangiosarcoma. There could be other types of tumors but hemangiosarcoma is most common. There are likely metastatic sites in other organs including liver, spleen and kidney. An unfavorable prognosis is warranted even with no cells identified in this effusion.

SEX

Female Spayed

AGE

12y

WEIGHT

50 lbs

HOSPITAL NAME

Scanvet

REFERRING VET

Dr. Sheridan

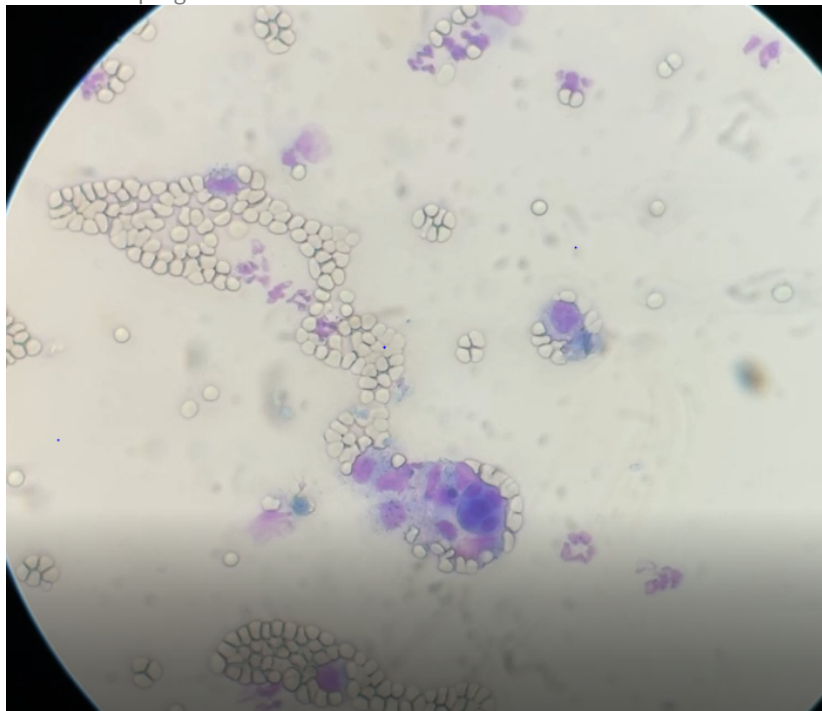


Image shows reactive mesothelial cells, neutrophils and RBCs collected from the pericardial effusion from Roxie. The mesothelial cells contain RBCs.

INVOICE NUMBER

856



DATE

12/15/22

The information and recommendations provided are based on the images presented by the referring veterinarian. No evaluation can be communicated regarding pathology that was not visible in the image/video clips provided.

INTERPRETED BY

L.D. McGill, DVM,
Ph.D, DACVP

Thank you for this referral. If the clinical or image interpretation does not parallel your findings or if I can be of any further assistance please contact me.

PATIENT

Roxie Burnsworth

L.D. McGill, DVM, Ph.D., DACVP
8288 Top of the World Drive
Cottonwood Heights, UT 84121
ldmcgill.vetpath@gmail.com
cell: 801-865-1220

SPECIES

Canine

BREED

Bull Terrier Mix

SEX

Female Spayed

AGE

12y

WEIGHT

50 lbs

HOSPITAL NAME

Scanvet

REFERRING VET

Dr. Sheridan

INVOICE NUMBER

856