



DATE PRESENTING CLINICAL SIGNS

12/10/21

Intermittent fecal incontinency Vomiting/diarrhea. U/S findings: The spleen was largely normal with mild, coarse architecture and heterogenous changes. A focal splenic nodule was noted and measured 1.6 cm at the cranial body with minor disruption of architecture.

INTERPRETED BY CYTOLOGY SUBMISSION

Spleen

L.D. McGill, DVM,
Ph.D, DACVP

OBSERVATIONS

Spleen: Submitted are 5 excellent videos of cells collected from the spleen in Neptune. The cellularity is mixed with scattered neutrophils interspersed with lymphoid cells, macrophages and nucleated red blood cells. The cellularity is mixed throughout the smears. There are aggregates of macrophages in several locations. Degenerate cells are occurring in the collection. Some fields have many more neutrophils than others. There are reactive lymphoid cells but malignant characteristics are not identified.

PATIENT

Neptune Machado

SPECIES INTERPRETATION OF THE FINDINGS & FURTHER RECOMMENDATIONS

Canine

Spleen - Marked splenic cellular hyperplasia consistent with chronic suppurative splenitis and reactive lymphoid tissue.

BREED COMMENTS

Poodle

The splenic tissue demonstrates a mixed cellular collection. There is an outside possibility of early lymphoma but the cellularity is not diagnostic. This is suggestive of some type of inflammation in the abdominal cavity which may be leaking to the spleen. This inflammation could be from the intestine or other locations in the abdominal cavity including pancreas. The intestinal clinical signs suggest some type of problem in the intestine or associated with the digestive tract. Further evaluation of the digestive tract and pancreas is encouraged in Neptune. The splenic cellularity is likely secondary to what is occurring in other organs. There is no suggestion of sepsis nor is the cellularity diagnostic for neoplasia.

SEX

Male

AGE

10y

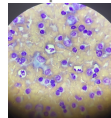


Image shows the mixed cell collection from the spleen in Neptune. Note the lymphocytes, nucleated RBCs, neutrophils and macrophages.

WEIGHT

18.4 lbs

The information and recommendations provided are based on the images presented by the referring veterinarian. No evaluation can be communicated regarding pathology that was not visible in the image/video clips provided.

HOSPITAL NAME

Rockaway Animal
Hospital

Thank you for this referral. If the clinical or image interpretation does not parallel your findings or if I can be of any further assistance please contact me.

REFERRING VET

Dr. Maniar

L.D. McGill, DVM, Ph.D., DACVP
8288 Top of the World Drive
Cottonwood Heights, UT 84121
ldmcgill.vetpath@gmail.com
cell: 801-865-1220

INVOICE NUMBER

641



DATE

12/10/21

INTERPRETED BY

L.D. McGill, DVM,
Ph.D, DACVP

PATIENT

Neptune Machado

SPECIES

Canine

BREED

Poodle

SEX

Male

AGE

10y

WEIGHT

18.4 lbs

HOSPITAL NAME

Rockaway Animal
Hospital

REFERRING VET

Dr. Maniar

INVOICE NUMBER

641