

DATE PRESENTING CLINICAL SIGNS

11/9/22

Small growth on right side of face. Owner just noticed recently.

INTERPRETED BY CYTOLOGY SUBMISSION

L.D. McGill, DVM,
Ph.D, DACVP

FNA of Skin lesion on right side of face

PATIENT

Daisy Ward

OBSERVATIONS

Skin lesion on right side of face: Submitted are 4 excellent videos of moderate collections of cells from the lesion on the right side of the face on Daisy. The cellularity is mixed. There are large numbers of small mature lymphocytes interspersed with scattered reactive lymphocytes. Macrophages are prominent. They have a foamy cytoplasm. There are rare neutrophils and red blood cells. Atypical cells with characteristics of malignancy are not identified.

SPECIES

Canine

INTERPRETATION OF THE FINDINGS & FURTHER RECOMMENDATIONS

Skin lesion - Granulomatous and lymphocytic inflammatory reaction.

BREED

English Bulldog

COMMENTS

The cellularity in this collection is consistent with that of a chronic inflammatory process. It may be a regressing histiocytoma. It could also be the result of a localized foreign body penetration. There is no suggestion of malignancy in the collection. There is no suggestion of sepsis. Treatment with anti-inflammatory agents may be beneficial. If the lesion enlarges, then excision may be required but cytologically this collection is benign.

SEX

FS

AGE

1y

WEIGHT

49.9

HOSPITAL NAME

Rotterdam Veterinary
Hospital

REFERRING VET

Dr. Melodee Kopa

INVOICE NUMBER

40640

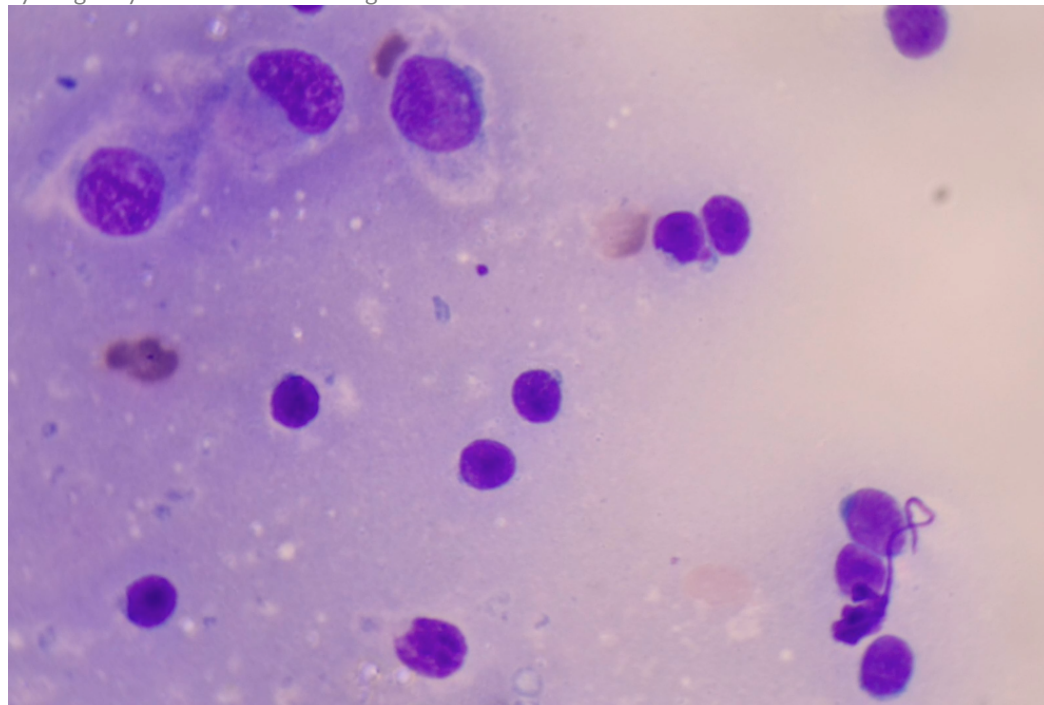
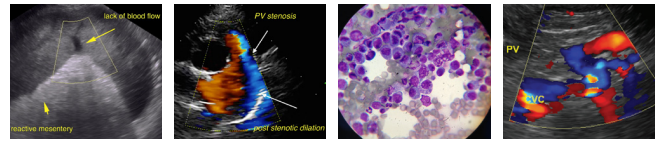


Image shows small mature lymphocytes with 3 macrophages in the upper left area of the image. Neoplastic change is not identified.



DATE

11/9/22

The information and recommendations provided are based on the images presented by the referring veterinarian. No evaluation can be communicated regarding pathology that was not visible in the image/video clips provided.

INTERPRETED BY

L.D. McGill, DVM,
Ph.D, DACVP

Thank you for this referral. If the clinical or image interpretation does not parallel your findings or if I can be of any further assistance, please contact me.

PATIENT

Daisy Ward

L.D. McGill, DVM, Ph.D., DACVP
8288 Top of the World Drive
Cottonwood Heights, UT 84121
ldmcgill.vetpath@gmail.com
cell: 801-865-1220

SPECIES

Canine

BREED

English Bulldog

SEX

FS

AGE

1y

WEIGHT

49.9

HOSPITAL NAME

Rotterdam Veterinary
Hospital

REFERRING VET

Dr. Melodee Kopa

INVOICE NUMBER

40640