



DATE PRESENTING CLINICAL SIGNS

11/7/22

Hyperthyroid, frequent vomiting, on abdominal ultrasound - enlarged pancreas with few hypoechoic nodules (2 cm diameter)
fPL increased, Lymphocyte count increased

INTERPRETED BY CYTOLOGY SUBMISSION

L.D. McGill, DVM, Ph.D,
DACVP

Pancreas

OBSERVATIONS

Pancreas: Submitted are 5 excellent videos and 4 images of cells collected from the pancreas in Nick. The cellularity is consistent through all the videos and images. The cells are rounded cells with minimal cytoplasm. The cells are characteristic of lymphoid cells and there is a variation in size and shape. There are good numbers of small mature lymphocytes but there are reactive lymphoid cells that are intermediate. There are scattered atypical cells, macrophages, neutrophils and degenerate cells. The uniformity of aspiration of lymphoid cells is atypical for the pancreas.

PATIENT

Nick Barone

SPECIES INTERPRETATION OF THE FINDINGS & FURTHER RECOMMENDATIONS

Felne

Pancreas - Lymphoid collection suggestive of lymphoma in the pancreas.

COMMENTS

BREED

DSH

The cellularity is strongly supportive of a lymphoma in this location. There is mild inflammation. The lymphoid cellularity is consistent. Confirmation of the cellularity can be accomplished by PARR testing on these slides or a follow up biopsy. My concern is that other organs are involved besides the pancreas. Aspiration of the liver and spleen may be beneficial in confirming the extent of lymphocytic infiltration in Nick. There are rare cases of lymphoma being primary in the pancreas but I would expect other organs to be involved as well. An unfavorable prognosis is warranted, in my opinion.

SEX

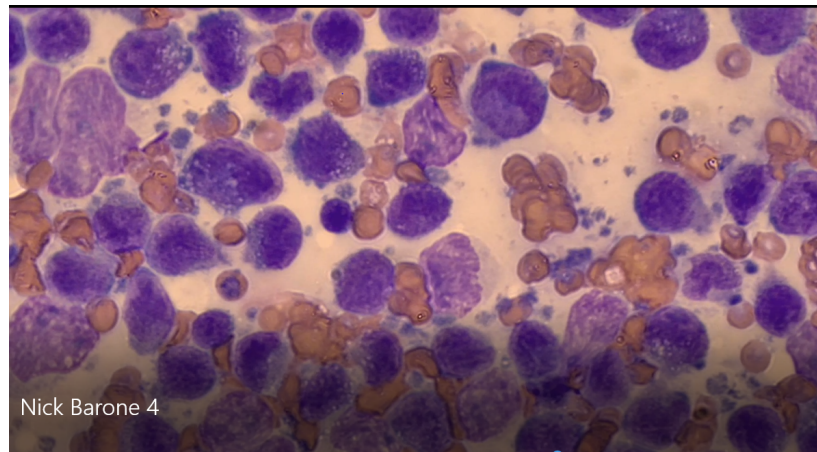
Male Neutered

AGE

14y

WEIGHT

10.4 lbs



HOSPITAL NAME

Central Veterinary
Hospital

Image shows a field of lymphoid cells collected from Nick. There is a small mature lymphocyte in the center whereas the other lymphoid cells are enlarged. There are prominent lymphoglandular bodies between cells.

REFERRING VET

Dr. St. Sir

The information and recommendations provided are based on the images presented by the referring veterinarian. No evaluation can be communicated regarding pathology that was not visible in the image/video clips provided.

Thank you for this referral. If the clinical or image interpretation does not parallel your findings or if I can be of any further assistance please contact me.

INVOICE NUMBER

834



DATE L.D. McGill, DVM, Ph.D., DACVP

11/7/22
8288 Top of the World Drive
Cottonwood Heights, UT 84121
ldmcgill.vetpath@gmail.com
cell: 801-865-1220

INTERPRETED BY

L.D. McGill, DVM, Ph.D,
DACVP

PATIENT

Nick Barone

SPECIES

Felne

BREED

DSH

SEX

Male Neutered

AGE

14y

WEIGHT

10.4 lbs

HOSPITAL NAME

Central Veterinary
Hospital

REFERRING VET

Dr. St. Sir

INVOICE NUMBER

834