



DATE PRESENTING CLINICAL SIGNS

11/30/22

Elevated LE, on Denamarin.
ALP 251, ALT 467, BUN 35.
AUS: mild to moderate hepatomegaly, with rounded edges. Both adrenals measure upper limit of normal for size. Aging changes in kidneys.

INTERPRETED BY

L.D. McGill, DVM,
Ph.D, DACVP

CYTOLOGY SUBMISSION

Liver

OBSERVATIONS

Liver: Submitted are 8 excellent videos of very good collections of cells from the liver in Koda. There are good collections of hepatocytes in all of the videos. The hepatocytes demonstrate vacuolated cytoplasm with lipid in some of the cytoplasm in various situations. This is present in several focal regions. The surrounding red blood cells include protein, lipid and a mixture of inflammatory cells including neutrophils and small lymphocytes. Malignant criteria are not identified.

PATIENT

Koda Whirley

SPECIES

Canine

INTERPRETATION OF THE FINDINGS & FURTHER RECOMMENDATIONS

Liver - Hepatocellular vacuolization with some lipidosis and mild inflammation.

BREED

Pomeranian mix

COMMENTS

The cellularity in this collection consists of very good hepatocytes with vacuolization. The multifocal areas of lipidosis are consistent with changes that can be seen with steroid hepatopathy. There appears to be mild fibrosis in some fields. There is minimal inflammation. There is no suggestion of neoplasia in this collection. Your suspicion of early Cushing's disease is very possible. A guarded prognosis is warranted and further diagnostic evaluation for Cushing's disease is encouraged.

SEX

Male Neutered

AGE

13y

WEIGHT

32 lbs

HOSPITAL NAME

Scanvet

REFERRING VET

Dr. Bennett

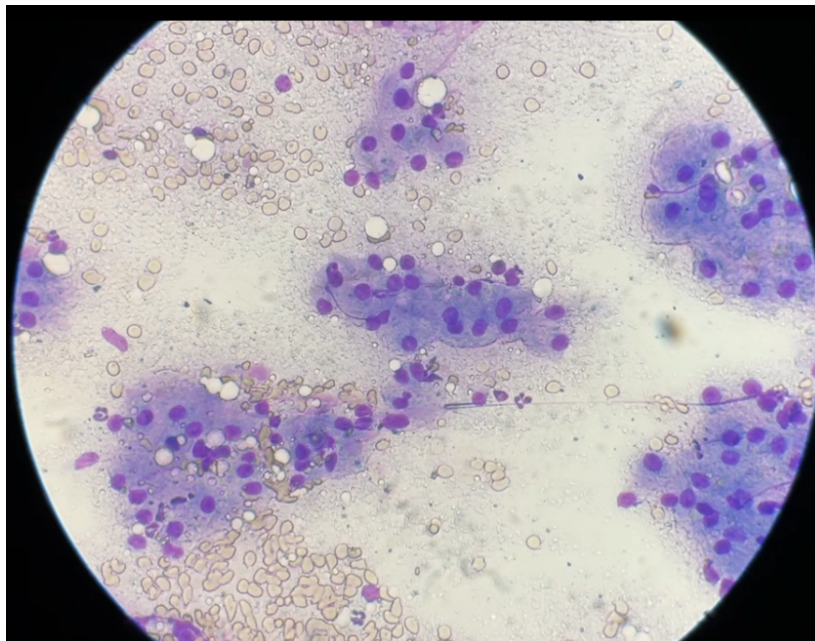


Image shows hepatocytes collected from the liver in Koda. Note the lipid vacuoles and scattered neutrophils.

INVOICE NUMBER

842



DATE 11/30/22 The information and recommendations provided are based on the images presented by the referring veterinarian. No evaluation can be communicated regarding pathology that was not visible in the image/video clips provided.

INTERPRETED BY L.D. McGill, DVM, Ph.D., DACVP Thank you for this referral. If the clinical or image interpretation does not parallel your findings or if I can be of any further assistance please contact me.

L.D. McGill, DVM,
Ph.D., DACVP

L.D. McGill, DVM, Ph.D., DACVP
8288 Top of the World Drive
Cottonwood Heights, UT 84121
ldmcgill.vetpath@gmail.com
cell: 801-865-1220

PATIENT

Koda Whirley

SPECIES

Canine

BREED

Pomeranian mix

SEX

Male Neutered

AGE

13y

WEIGHT

32 lbs

HOSPITAL NAME

Scanvet

REFERRING VET

Dr. Bennett

INVOICE NUMBER

842