



**DATE PRESENTING CLINICAL SIGNS**

11/23/22

Patient had a lipoma underneath this capsule that we aspirated for about 6 months. This is a capsule that was noticed a few weeks ago, it seems like its attached to the lipoma.

**CYTOLOGY SUBMISSION**

**INTERPRETED BY**

Subcutaneous mass

L.D. McGill, DVM,  
Ph.D, DACVP

**OBSERVATIONS**

Subcutaneous mass: Submitted are 8 excellent videos of excellent collections of cells from the subcutaneous mass on Loki. The cells are consistent throughout the videos. These cells all have characteristics of adipocytes. Some of the cells have large vacuoles and others are aggregated. The nuclei are pressed against the cell wall. Some of the vacuoles are multiple. These are characteristics of a lipoma.

**PATIENT**

Loki Kloss

**INTERPRETATION OF THE FINDINGS & FURTHER RECOMMENDATIONS**

Subcutaneous mass - Lipoma

**SPECIES**

Canine

**COMMENTS**

The cellularity on these excellent collections are characteristic of lipoma. The mass may be multilobulated. There is no suggestion of malignancy or other cellular infiltration. Excision is expected to be curative. These growths may occur irregularly in other locations. Removal is always in order followed by a biopsy to make certain there are no other tumor processes associated.

**BREED**

Corgi

**SEX**

Female Spayed

**AGE**

9y

**WEIGHT**

25 lbs

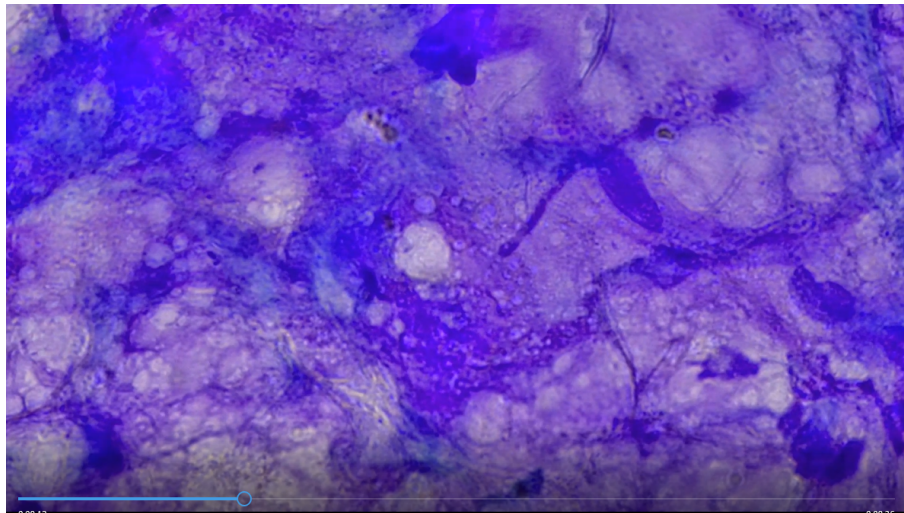


Image shows a group of adipocytes collected from the subcutaneous mass in Loki. Note the irregular vacuoles.

**HOSPITAL NAME**

Central Veterinary  
Hospital

**REFERRING VET**

Dr. St. Sir

The information and recommendations provided are based on the images presented by the referring veterinarian. No evaluation can be communicated regarding pathology that was not visible in the image/video clips provided.

Thank you for this referral. If the clinical or image interpretation does not parallel your findings or if I can be of any further assistance please contact me.

**INVOICE NUMBER**

839



**DATE** L.D. McGill, DVM, Ph.D., DACVP

11/23/22  
8288 Top of the World Drive  
Cottonwood Heights, UT 84121  
ldmcgill.vetpath@gmail.com  
cell: 801-865-1220

**INTERPRETED BY**

L.D. McGill, DVM,  
Ph.D, DACVP

**PATIENT**

Loki Kloss

**SPECIES**

Canine

**BREED**

Corgi

**SEX**

Female Spayed

**AGE**

9y

**WEIGHT**

25 lbs

**HOSPITAL NAME**

Central Veterinary  
Hospital

**REFERRING VET**

Dr. St. Sir

**INVOICE NUMBER**

839