



DATE PRESENTING CLINICAL SIGNS

11/21/22

Patient presented 11/21/22 with new mass on left pinna. Patient recently had similar mass located on right abdomen aspirated and sent to Sonopath, Invoice Number 829. Owner says growth on pinna appeared and grew quickly since abdomen growth aspirated. Abdomen mass has grown since last aspirate also.

INTERPRETED BY

L.D. McGill, DVM,
Ph.D, DACVP

CYTOLOGY SUBMISSION

FNA of Ear mass

PATIENT

Reese D'Amico

OBSERVATIONS

Ear mass: Submitted are 2 excellent videos of massive numbers of cells collected from the left pinna mass on Reese. The cellularity is consistent round cells with prominent cytoplasm and eccentric nuclei. There is a halo on one side of the nucleus in many of the cells. There are prominent multinucleated cells. There is some granularity in the background. Some protein is prominent. in the background. There are very few RBCs.

SPECIES

Canine

BREED

Lab Retriever

INTERPRETATION OF THE FINDINGS & FURTHER RECOMMENDATIONS

Ear mass - Round cell tumor consistent with Plasmacytoma

SEX

Male Neutered

COMMENTS

The cellularity strongly supports a plasmacytoma. This is a common location for those benign growths. The granularity is slightly confusing, but the nuclei are not consistent with mast cells. The eccentric nuclei, multinucleated cells and halos on the side of some nuclei are consistent with plasma cells. Complete excision of these tumors results in a favorable prognosis. I suspect that this growth is completely separate from the other mass.

AGE

10y

WEIGHT

57.2#

HOSPITAL NAME

Rotterdam Veterinary
Hospital

REFERRING VET

Dr. Melodee Kopa

INVOICE NUMBER

40650



DATE

11/21/22

INTERPRETED BY

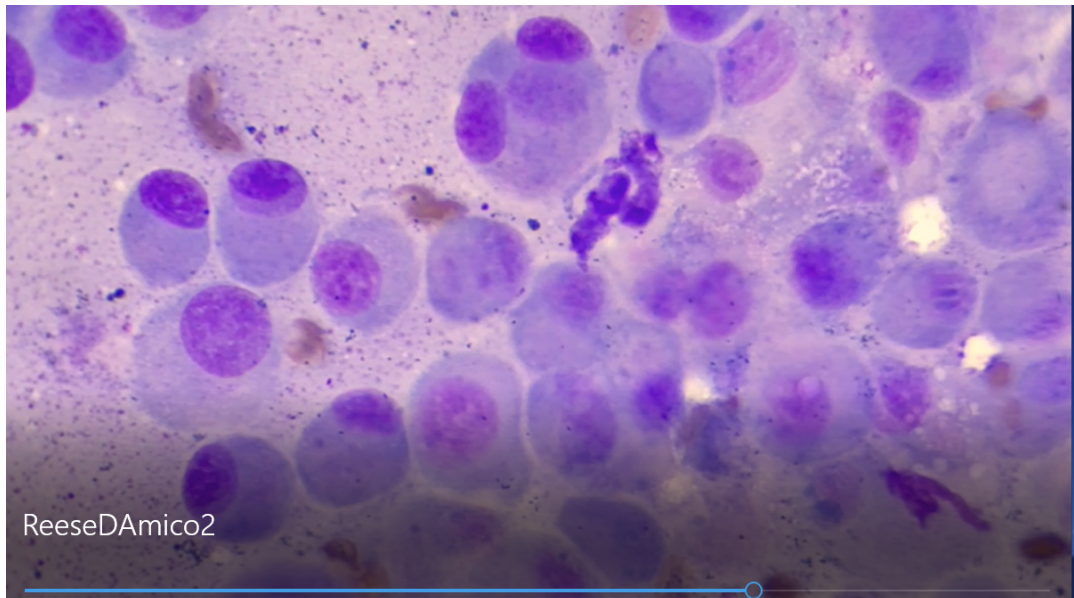
L.D. McGill, DVM,
Ph.D, DACVP

PATIENT

Reese D'Amico

SPECIES

Canine



BREED

Lab Retriever

The information and recommendations provided are based on the images presented by the referring veterinarian. No evaluation can be communicated regarding pathology that was not visible in the image/video clips provided.

SEX

Male Neutered

Thank you for this referral. If the clinical or image interpretation does not parallel your findings or if I can be of any further assistance, please contact me.

AGE

10y

L.D. McGill, DVM, Ph.D., DACVP
8288 Top of the World Drive
Cottonwood Heights, UT 84121
ldmcgill.vetpath@gmail.com
cell: 801-865-1220

WEIGHT

57.2#

HOSPITAL NAME

Rotterdam Veterinary
Hospital

REFERRING VET

Dr. Melodee Kopa

INVOICE NUMBER

40650