



DATE PRESENTING CLINICAL SIGNS

11/17/21

Hx of very enlarged testicle, thoracic mass. 2 masses on spleen distorting the contour; several enlarged LN.

INTERPRETED BY CYTOLOGY SUBMISSION

L.D. McGill, DVM,
Ph.D, DACVP

FNA performed on the spleen.

PATIENT

Melvin Stevens

OBSERVATIONS

Spleen: Submitted are 4 excellent videos of moderate to excellent collections of cells from the spleen in Melvin. There is also one image. The videos consist of a mixture of cells, the majority of which are nucleated RBCs. There are scattered lymphocytes and neutrophils. Megakaryocytes are part of the process. The nucleated RBCs appear to be prominent and proliferating in normal patterns. Specific criteria of malignancy are not identified. There were scattered mitotic figures, but this may occur in active hematopoiesis.

SPECIES

Canine

INTERPRETATION OF THE FINDINGS & FURTHER RECOMMENDATIONS

Spleen - Prominent hematopoiesis with evidence of mild suppurative splenitis.

BREED

English Bulldog

COMMENTS

The changes in this collection suggest the likelihood of hematopoietic nodules in this spleen. This is not uncommon in dogs. I was unable to identify neoplastic tissue or changes that would support a specific process. I suspect that these changes are secondary to the other problems in the dog.

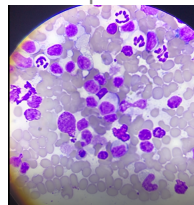
SEX

Male intact

Treatment for inflammation is encouraged. If problems continue, aspiration of other structures including masses or lymph nodes may be required to identify the underlying process. Lymphoma cannot be ruled out with this collection, but it cannot be diagnosed from the cells either. The hematopoietic tissue did not appear to be neoplastic in this collection.

AGE

6 years



WEIGHT

51.33#

Image shows a representative cellular collection from the spleen in Melvin. Note the NRBCs and scattered neutrophils. This is the most prominent cellularity.

HOSPITAL NAME

Tranquility Veterinary
Clinic

The information and recommendations provided are based on the images presented by the referring veterinarian. No evaluation can be communicated regarding pathology that was not visible in the image/video clips provided.

Thank you for this referral. If the clinical or image interpretation does not parallel your findings or if I can be of any further assistance, please contact me.

REFERRING VET

Dr. Jones

L.D. McGill, DVM, Ph.D., DACVP

8288 Top of the World Drive
Cottonwood Heights, UT 84121
ldmcgill.vetpath@gmail.com

INVOICE NUMBER

70422

cell: 801-865-1220



DATE

11/17/21

INTERPRETED BY

L.D. McGill, DVM,
Ph.D, DACVP

PATIENT

Melvin Stevens

SPECIES

Canine

BREED

English Bulldog

SEX

Male intact

AGE

6 years

WEIGHT

51.33#

HOSPITAL NAME

Tranquility Veterinary
Clinic

REFERRING VET

Dr. Jones

INVOICE NUMBER

70422