



**DATE PRESENTING CLINICAL SIGNS**

11/17/21 US showed hypoechoic , enlarged spleen with irregular contour. Diameter 1.15cm. FNA of spleen performed. Mass effect on rads in cranial mediastinum.

**INTERPRETED BY CYTOLOGY SUBMISSION**

L.D. McGill, DVM,  
Ph.D, DACVP

FNA of Spleen

**PATIENT OBSERVATIONS**

Fuzzy Ippolito  
Spleen: Submitted are 6 excellent videos of moderate collections of cells from the spleen in Fuzzy. The cellularity is mixed. There are large numbers of neutrophils interspersed with scattered lymphocytes and rare nucleated red blood cells. Packets of platelets are present. Scattered aggregates of cells are necrotic. The neutrophils are prominent in many of the fields. Criteria of malignancy are not identified.

**SPECIES**

feline

**INTERPRETATION OF THE FINDINGS & FURTHER RECOMMENDATIONS**

Spleen - Chronic suppurative splenitis with necrotic cells.

**BREED**

DSH

**COMMENTS**

The cellularity in this collection supports a chronic inflammatory process within the spleen or draining to the spleen. There is no suggestion of neoplasia in any of the cells. This inflammatory process could be from the pancreas or intestine or even a possibility of FIP although it is not classical for that condition. Treatment for inflammation is encouraged. Exploratory and biopsy may be required to confirm the underlying process.

**SEX**

FS

**AGE**

14 years

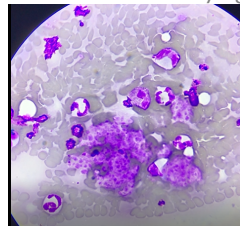


Image shows a representative field of cells collected from Fuzzy. Note the neutrophils and platelet aggregates. There is an eosinophil in the center.

**WEIGHT**

8.2#

The information and recommendations provided are based on the images presented by the referring veterinarian. No evaluation can be communicated regarding pathology that was not visible in the image/video clips provided.

**HOSPITAL NAME**

Tranquility Veterinary  
Clinic

Thank you for this referral. If the clinical or image interpretation does not parallel your findings or if I can be of any further assistance please contact me.

**REFERRING VET**

Dr. Kurapati

L.D. McGill, DVM, Ph.D., DACVP  
8288 Top of the World Drive  
Cottonwood Heights, UT 84121  
ldmcgill.vetpath@gmail.com  
cell: 801-865-1220

**INVOICE NUMBER**

70421



**DATE**

11/17/21

**INTERPRETED BY**

L.D. McGill, DVM,  
Ph.D, DACVP

**PATIENT**

Fuzzy Ippolito

**SPECIES**

feline

**BREED**

DSH

**SEX**

FS

**AGE**

14 years

**WEIGHT**

8.2#

**HOSPITAL NAME**

Tranquility Veterinary  
Clinic

**REFERRING VET**

Dr. Kurapati

**INVOICE NUMBER**

70421