



**DATE PRESENTING CLINICAL SIGNS**

11/16/22

Recent adoption. O notice lump on right hind leg lateral aspect just proximal to stifle  
Severe periodontal disease. Approximately 2 cm mass, just proximal to stifle.

**CYTOLOGY SUBMISSION**

**INTERPRETED BY**

Dermal mass

L.D. McGill, DVM,  
Ph.D, DACVP

**OBSERVATIONS**

Right hind leg mass: Submitted are 13 excellent images of very good collections of cells from the right hindleg mass on Sadie. The cellularity is consistent throughout all of the images. The cellularity consists of a proliferation of round cells with round nuclei. The cytoplasm is filled with granular material which is metachromatic to deep purple. Most of the cells are well granulated. Some are mildly granulated. There are rare eosinophils. The round cells are characteristic mast cells.

**PATIENT**

Sadie Miller

**INTERPRETATION OF THE FINDINGS & FURTHER RECOMMENDATIONS**

Right hind leg mass - Mast cell tumor (see comments)

**SPECIES**

Canine

**COMMENTS**

The cellularity in this collection is characteristic of a mast cell tumor which is rather well granulated. This suggests a low-grade mast cell tumor. Some of the cells are not as well granulated as others and thus this could be either grade 1 or grade 2 mast cell tumor. Excision of the lesion will be required to confirm grade and margins. Chemotherapy may be worth attempting in this case. A guarded prognosis is always warranted with mast cell tumors. The regional lymph node should be evaluated for potential metastatic sites. If the lymph node is involved, then internal evaluation of the spleen and liver is encouraged.

**BREED**

Mix

**SEX**

Female Spayed

**AGE**

12y

**WEIGHT**

12

**HOSPITAL NAME**

Torch Lake Veterinary  
Clinic

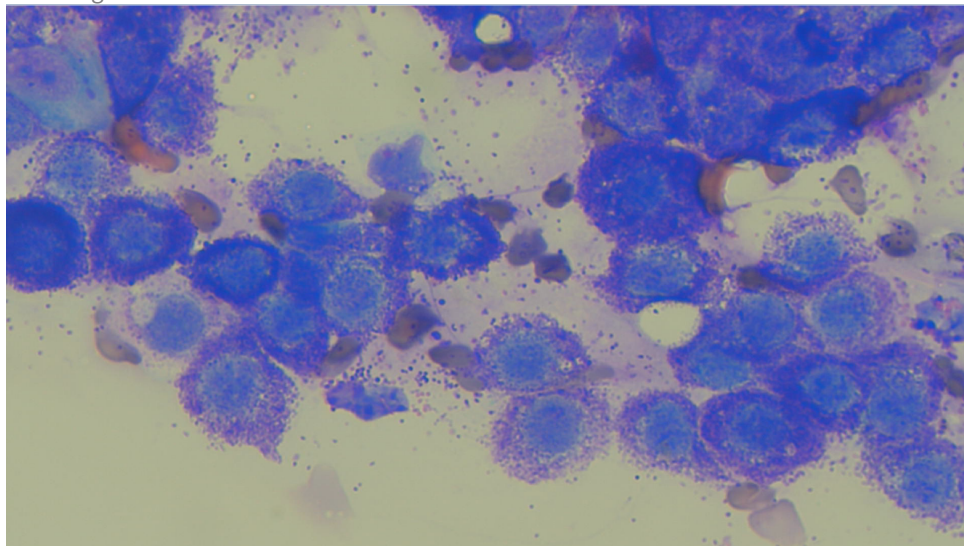


Image shows a group of mast cells collected from the right hind leg mass on Sadie. Most of the cells are well granulated. There are free granules in the background.

**REFERRING VET**

Dr. Waffle

The information and recommendations provided are based on the images presented by the referring veterinarian. No evaluation can be communicated regarding pathology that was not visible in the image/video clips provided.

**INVOICE NUMBER**

837



**DATE** Thank you for this referral. If the clinical or image interpretation does not parallel your findings or if I can be of any further assistance please contact me.

11/16/22

**INTERPRETED BY** L.D. McGill, DVM, Ph.D., DACVP  
8288 Top of the World Drive  
Cottonwood Heights, UT 84121  
ldmcgill.vetpath@gmail.com  
cell: 801-865-1220

**PATIENT**

Sadie Miller

**SPECIES**

Canine

**BREED**

Mix

**SEX**

Female Spayed

**AGE**

12y

**WEIGHT**

12

**HOSPITAL NAME**

Torch Lake Veterinary  
Clinic

**REFERRING VET**

Dr. Waffle

**INVOICE NUMBER**

837