



**DATE** **PRESENTING CLINICAL SIGNS**  
11/10/22 Acute peripheral lymphadenopathy, cough  
CBC and Chemistry wnl

**INTERPRETED BY** **CYTOLOGY SUBMISSION**  
L.D. McGill, DVM, Ph.D, DACVP Prescapular lymph node

**OBSERVATIONS**  
Prescapular lymph node: Submitted are 2 excellent videos of moderate to excellent cellular collections from the prescapular lymph node on lpo. The cellularity is consistent throughout these collections. The lymphoid cells are large with nuclei that are 2 to 4 times the size of red blood cells. There are scattered small lymphocytes in the collection. Degenerate debris is present. Large numbers of atypical lymphoid cells are not identified. The large lymphoid cells include prominent nucleoli and anisokaryosis. The cytoplasm is minimal and bluish gray.

**PATIENT**  
lpo Beechie

**INTERPRETATION OF THE FINDINGS & FURTHER RECOMMENDATIONS**  
Prescapular lymph node - Suggestive of early high-grade lymphoma.

**SPECIES**

Canine

**COMMENTS**  
The cellularity in this lymph node collection suggests an increased number of irregular atypical lymphoid cells. The cells have prominent nucleoli and irregular nuclei. The cytoplasm is minimal. Degenerate debris is scattered throughout with very few inflammatory cells. If chemotherapy is contemplated, then immunophenotyping of the cells to confirm the specific cell type may be beneficial for prognosis. The slides may be submitted for PARR testing or new slides that are not stained can be submitted for immunocytochemistry staining. Flow cytometry can be beneficial but will require a repeat collection of cells prior to submission to the laboratory. Contacting the laboratory to confirm how to submit flow cytometry samples is encouraged. A guarded prognosis is warranted due to the irregular cells. Excision of this lymph node may be beneficial in treating lpo. Further evaluation of other lymph nodes to determine whether other nodes are involved is important in treating this case and staging the process. A guarded to unfavorable prognosis is warranted, in my opinion.

**BREED**

Shepherd X

**SEX**

Female Spayed

**AGE**

14y

**WEIGHT**

62#

**HOSPITAL NAME**

Ruidoso Animal Clinic

**REFERRING VET**

Dr. Favis

**INVOICE NUMBER**

836

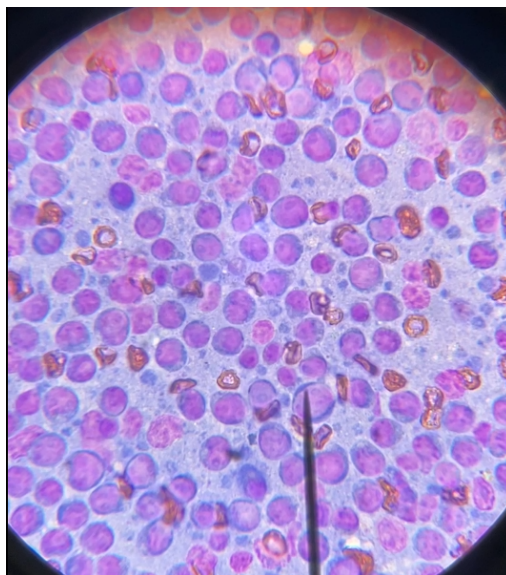


Image shows a representative collection of cells from the prescapular lymph node on lpo. Note the larger lymphoid cells with prominent nucleoli in the large irregular lymphoid cells.



**DATE**

11/10/22

The information and recommendations provided are based on the images presented by the referring veterinarian. No evaluation can be communicated regarding pathology that was not visible in the image/video clips provided.

**INTERPRETED BY**

L.D. McGill, DVM, Ph.D,  
DACVP

Thank you for this referral. If the clinical or image interpretation does not parallel your findings or if I can be of any further assistance please contact me.

**L.D. McGill, DVM, Ph.D., DACVP**

8288 Top of the World Drive  
Cottonwood Heights, UT 84121  
ldmcgill.vetpath@gmail.com  
cell: 801-865-1220

**PATIENT**

Ipo Beechie

**SPECIES**

Canine

**BREED**

Shepherd X

**SEX**

Female Spayed

**AGE**

14y

**WEIGHT**

62#

**HOSPITAL NAME**

Ruidoso Animal Clinic

**REFERRING VET**

Dr. Favis

**INVOICE NUMBER**

836