



DATE PRESENTING CLINICAL SIGNS

11/10/22

2 years old cat presented with the complaint of not eating properly since 2 days, he is peeing outside litter box, he peed on the owner today while sitting on her belly, he pooped once outside litter box as well yesterday, after that no poop until now, Upon physical examination A lump can be felt in abdomen.

INTERPRETED BY

The picture of mass seen on ultrasound is attached, this cat presented to us in March 2022 and diagnosed with FIP and owner treated her with FIP medication for 45 days

L.D. McGill, DVM,
Ph.D, DACVP

PATIENT CYTOLOGY SUBMISSION

FNA of mass cranial to the left kidney

Butt Louise

SPECIES OBSERVATIONS

Cat

Mass anterior to kidney: Submitted is a single video with large numbers of images collected from the mass anterior to the kidney in Butt. The cellularity consists almost entirely of round cells that are small with dark nuclei. They have minimal cytoplasm. There are some cells that are slightly larger, but they are not blastic or atypical. Scattered neutrophils and scattered macrophages are identified. Malignant criteria are not identified.

BREED

Persian

INTERPRETATION OF THE FINDINGS & FURTHER RECOMMENDATIONS

SEX

Mass anterior to kidney - Lymphoid collection consistent with reactive lymph node and mild suppurative lymphadenitis.

Male

AGE COMMENTS

2y

The cellularity is consistent with a reactive lymph node in the abdominal cavity of the cat. This can occur as individual reactions in some lymph nodes, or this may be secondary to other forms of inflammation in Butt. The cellularity is not characteristic of neoplasia. I cannot rule out the possibility of small cell lymphoma but that will require immunohistochemistry staining to confirm. In this instance I suspect that this is a reactive lymph node in the abdominal cavity of this cat or the result of some type of chronic inflammatory response in the posterior abdomen. I am unable to identify changes supportive of neoplasia or sepsis. There is an outside possibility that a chronic case of FIP may result in this type of inflammatory process. A guarded prognosis is warranted in light of this cellular inflammatory response.

WEIGHT

4.5

HOSPITAL NAME

Pawsitive Veterinary
Clinic Dubai Silicon
Oasis

REFERRING VET

Dr. Iftikhar

INVOICE NUMBER

40641



DATE

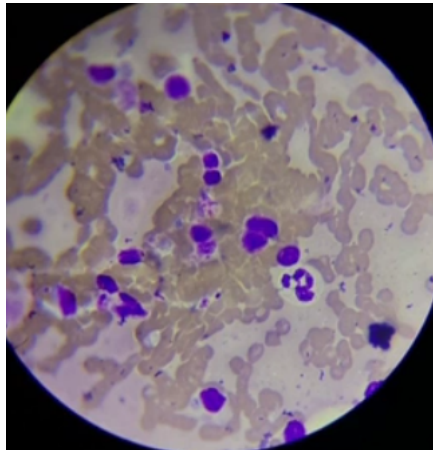
11/10/22

INTERPRETED BY

L.D. McGill, DVM,
Ph.D, DACVP

PATIENT

Butt Louise



SPECIES

Cat

Image shows the small lymphocytes and a neutrophil. Note the small size of the lymphocytes compared to the neutrophil. This is consistent throughout the collection of cells from Butt.

BREED

Persian

The information and recommendations provided are based on the images presented by the referring veterinarian. No evaluation can be communicated regarding pathology that was not visible in the image/video clips provided.

SEX

Male

L.D. McGill, DVM, Ph.D., DACVP
8288 Top of the World Drive
Cottonwood Heights, UT 84121
ldmcgill.vetpath@gmail.com
cell: 801-865-1220

AGE

2y

WEIGHT

4.5

HOSPITAL NAME

Pawsitive Veterinary
Clinic Dubai Silicon
Oasis

REFERRING VET

Dr. Iftikhar

INVOICE NUMBER

40641