

**PATIENT** **PRESENTING CLINICAL SIGNS**  
Lucy Slager FNA of liver after Ultrasound 10/22.

**CYTOLOGY SUBMISSION**  
FNA of liver.

**SPECIES** **OBSERVATIONS**

Canine Liver: Submitted are 7 excellent videos of cells collected from the liver in Lucy. There is a consistent finding throughout the hepatocytes. Almost all of the hepatocytes are vacuolated. Some of the hepatocytes appear to have lipid. The hepatocytes are aggregated in irregular patterns. They are not forming cord-like patterns of normal hepatocytes. The associated red blood cells and inflammatory elements are neutrophils and lymphocytes with no suggestion of neoplasia in any of the tissue.

**BREED**

German WHP

**INTERPRETATION OF THE FINDINGS & FURTHER RECOMMENDATIONS**

**SEX** Liver - Diffuse severe hepatocellular vacuolization with a suggestion of nodular hyperplasia.

**COMMENTS**

Female spayed The cellularity supports a rather uniform change throughout the hepatocytes. The vacuolization including lipidosis could be the result of metabolic liver disease. If this was throughout the liver, I would be concerned about pancreatitis or enteritis resulting in these changes. If this is a localized change, then metabolic liver changes or possibly nodular hyperplasia or an outside possibility of a more proliferative hepatocellular process should be considered. The cells appear to be proliferating in irregular patterns. Malignant characteristics are not identified in any other cellularity and particularly not identified overtly in the hepatocytes. At this time I'm concerned about the possibility of metabolic liver changes or nodular hyperplasia with some metabolic changes in the hepatocytes occurring in this liver biopsy from Lucy. If problems continue and further diagnosis is required, then a follow-up biopsy will likely be beneficial.

**AGE**

10-year-old

**WEIGHT**

38.6 lbs

Image below shows representative hepatocytes with lipid and vacuolization collected from Lucy. Note the irregular sizes of the hepatocytes.

**INTERPRETED BY**

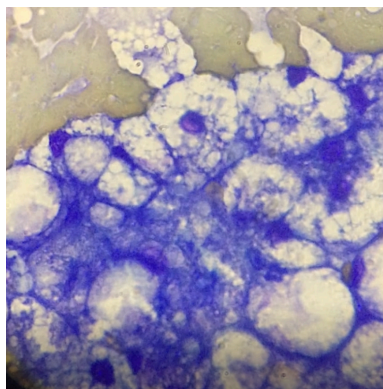
L.D. McGill, DVM,  
Ph.D, DACVP

**HOSPITAL NAME**

West Eugene AH

**REFERRING VET**

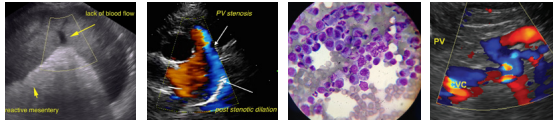
Dr. Powers



**DATE** The information and recommendations provided are based on the images presented by the referring veterinarian. No evaluation can be communicated regarding pathology that was not visible in the image/video clips provided.

11/1/2021

Thank you for this referral. If the clinical or image interpretation does not parallel your findings or



**PATIENT** if I can be of any further assistance please contact me.

Lucy Slager **L.D. McGill, DVM, Ph.D., DACVP**  
8288 Top of the World Drive  
Cottonwood Heights, UT 84121  
**SPECIES** ldmcgill.vetpath@gmail.com  
cell: 801-865-1220

Canine

**BREED**

German WHP

**SEX**

Female spayed

**AGE**

10-year-old

**WEIGHT**

38.6 lbs

**INTERPRETED BY**

L.D. McGill, DVM,  
Ph.D, DACVP

**HOSPITAL NAME**

West Eugene AH

**REFERRING VET**

Dr. Powers

**DATE**

11/1/2021