



DATE PRESENTING CLINICAL SIGNS

10/8/22

FNA-one site sublumbar LN. Diarrhea and decreased albumin. Current meds: Metro 500mg bid. U/S final report not back yet... Multiple enlarged LN's. thickened portion of SI, splenic nodule, scant free fluid.
Alb 1.8, Amylase 1397, CPK 1581, WBC 17,900, PMN's 15, 394, USG 1.030, Bilirubin 2+

INTERPRETED BY

L.D. McGill, DVM,
Ph.D, DACVP

CYTOLOGY SUBMISSION

Lymph node

OBSERVATIONS

PATIENT

Sheba McGlew

Lymph node: Submitted are several excellent videos of excellent collections of cells from the sub lumbar lymph node in Sheba. The cellularity consists of large numbers of round cells, the majority of which are large irregular atypical lymphoid cells. Many of the cells have prominent nucleoli. The cytoplasm is prominent and bluish gray. Mitotic figures are readily identified.

INTERPRETATION OF THE FINDINGS & FURTHER RECOMMENDATIONS

SPECIES

Canine

Sublumbar lymph node - Characteristic of high-grade lymphoma

COMMENTS

BREED

Rottweiler

The cellularity in this collection is characteristic of a high-grade lymphoma. There are many mitotic figures and the cells are quite large with prominent nucleoli. The nuclear characteristics are those of a malignant proliferative process. If chemotherapy is contemplated, then immunophenotyping of the cells to confirm the specific cell type may be beneficial for prognosis. The slides can be submitted for PCR testing or new slides that are not stained can be submitted for immunocytochemistry staining. Flow cytometry can be beneficial but will require a repeat collection of cells prior to submission to the laboratory. Contacting the laboratory to confirm how to submit flow cytometry samples is encouraged. An unfavorable prognosis is warranted in my opinion.

SEX

Female Spayed

AGE

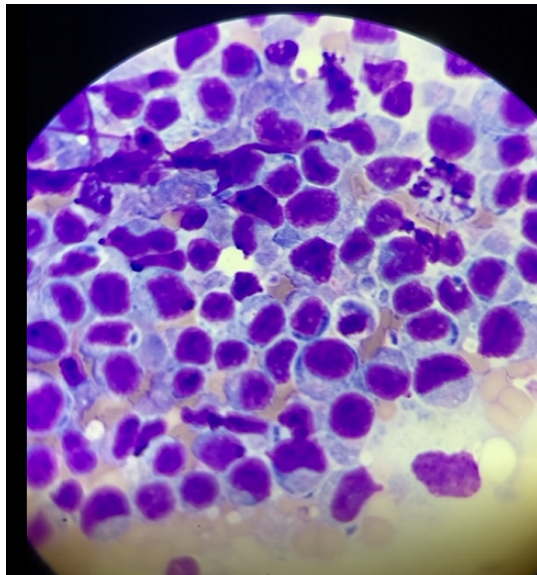
7y

WEIGHT

75#

HOSPITAL NAME

Tranquility Veterinary
Clinic



REFERRING VET

Dr. Christensen

Image shows a representative collection of cells from a sublumbar lymph node in Sheba. Note at least one mitotic figure and possibly more.

INVOICE NUMBER

821

The information and recommendations provided are based on the images presented by the referring veterinarian. No evaluation can be communicated regarding pathology that was not visible in the image/video clips provided.



DATE

10/8/22

Thank you for this referral. If the clinical or image interpretation does not parallel your findings or if I can be of any further assistance please contact me.

INTERPRETED BY

L.D. McGill, DVM,
Ph.D, DACVP

L.D. McGill, DVM, Ph.D., DACVP
8288 Top of the World Drive
Cottonwood Heights, UT 84121
ldmcgill.vetpath@gmail.com
cell: 801-865-1220

PATIENT

Sheba McGlew

SPECIES

Canine

BREED

Rottweiler

SEX

Female Spayed

AGE

7y

WEIGHT

75#

HOSPITAL NAME

Tranquility Veterinary
Clinic

REFERRING VET

Dr. Christensen

INVOICE NUMBER

821