



DATE **PRESENTING CLINICAL SIGNS**
10/7/22 Enlarged liver and spleen noted on ultrasound. History of weight loss. Chronic asthma/URI's and intermittent vomiting.

INTERPRETED BY **CYTOLOGY SUBMISSION**
Liver; spleen

L.D. McGill, DVM,
Ph.D, DACVP

OBSERVATIONS

Liver: Submitted are 4 excellent videos of excellent collections of hepatocytes from the liver in Meeko. The hepatocytes demonstrate vacuolization with mild granularity. There are scattered neutrophils and lymphocytes interspersed. Neoplastic cells are not identified. The hepatocytes appear to have early lipid.

PATIENT

Meeko Moore
Spleen: Submitted are 4 excellent videos of moderate to excellent collections of cells from the spleen in Meeko. The cellularity on two of the videos is most characteristic of a uniform cellularity of lymphoid cells. These lymphoid cells appeared to be large and atypical. Prominent nucleoli are identified. There is dark staining of these lymphoid cells. Degenerate debris is present. A few neutrophils are identified. Two of the videos demonstrate a hemorrhagic background interspersed with lymphocytes and inflammatory cells.

SPECIES

Feline

INTERPRETATION OF THE FINDINGS & FURTHER RECOMMENDATIONS

Liver - Mild hepatocellular vacuolization suggesting early feline fatty liver syndrome with minimal other cellular infiltration.

BREED

Spleen - Increased numbers of lymphoid cells suggesting early lymphoma.

DSH

COMMENTS

The changes in the spleen are of concern since there is an increased number of lymphoid cells and they appear to be atypical. The cellularity can be confirmed with PARR testing. This may be required particularly if chemotherapy is contemplated. The liver changes are secondary and could be due to any type of metabolic liver disease process. Inflammation is present. Exploratory and biopsy of the spleen may be required to confirm the underlying process if further therapy is contemplated.

AGE

16y

WEIGHT

10.9 lbs

HOSPITAL NAME

Rotterdam Veterinary
Hospital

REFERRING VET

Dr. St. Sir

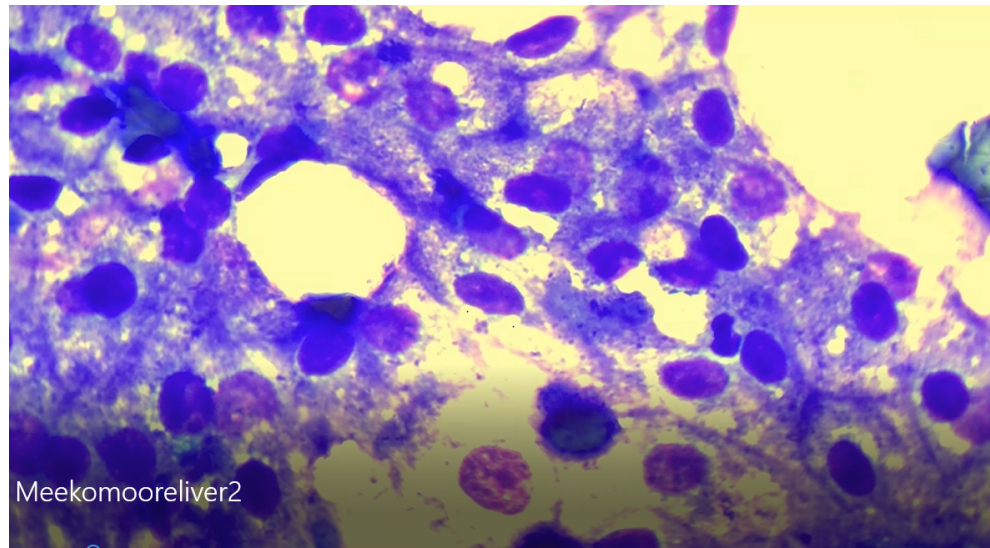


Image shows a field of hepatocytes with vacuolization and lipid collected from Meeko. There may be some lymphocytes present.

INVOICE NUMBER

821



DATE

10/7/22

INTERPRETED BY

L.D. McGill, DVM,
Ph.D., DACVP

PATIENT

Meeko Moore

SPECIES

Feline

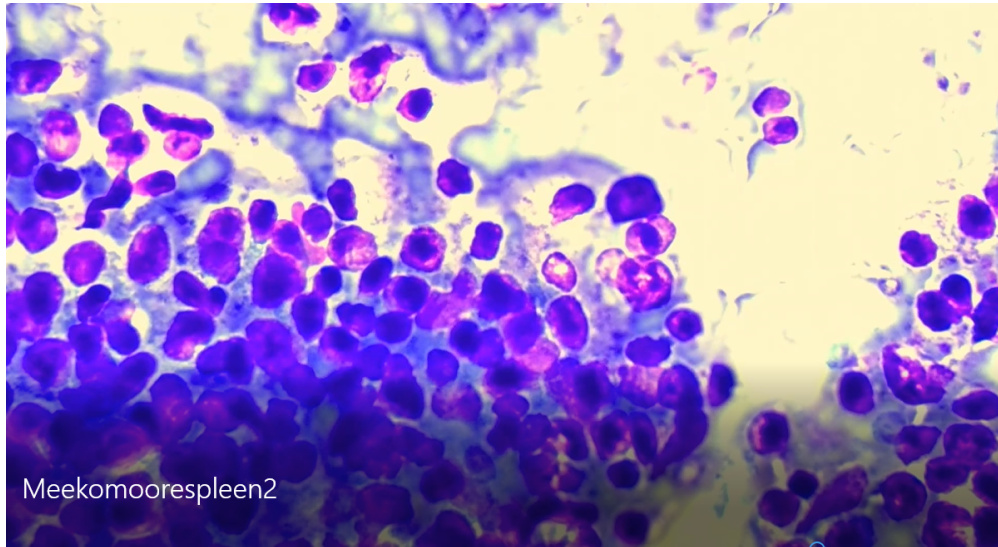


Image shows a group of lymphocytes collected from the spleen in Meeko. Note the prominent nucleoli.

BREED

DSH

The information and recommendations provided are based on the images presented by the referring veterinarian. No evaluation can be communicated regarding pathology that was not visible in the image/video clips provided.

SEX

Male Neutered

Thank you for this referral. If the clinical or image interpretation does not parallel your findings or if I can be of any further assistance please contact me.

AGE

16y

L.D. McGill, DVM, Ph.D., DACVP
8288 Top of the World Drive
Cottonwood Heights, UT 84121
ldmcgill.vetpath@gmail.com
cell: 801-865-1220

WEIGHT

10.9 lbs

HOSPITAL NAME

Rotterdam Veterinary
Hospital

REFERRING VET

Dr. St. Sir

INVOICE NUMBER

821