



DATE	PRESENTING CLINICAL SIGNS
10/7/21	Decreased appetite, weight loss, intermittent vomiting Chemistry wnl, CBC - mild leukocytosis; ultrasound - significant thickening (2cm) of gastric wall and proximal duodenum. Suspect neoplasia. Suspect LSA.
INTERPRETED BY	FNA of gastric wall taken.
L.D. McGill, DVM, Ph.D, DACVP	CYTOLOGY SUBMISSION Gastric Wall Aspiration
PATIENT	OBSERVATIONS
Zoey Hutson	Gastric Wall Aspiration: Submitted are 7 excellent videos of cells collected from the gastric wall in Zoey. There is a mixture of cells throughout these smears. There are focal areas of degeneration. There are large rounded cells with prominent nucleoli that have the appearance of atypical lymphoid cells. These cells are prominent with macrophages and neutrophils associated. There are aggregates of degenerate necrotic material. There are few aggregates of spindloid cells.
SPECIES	INTERPRETATION OF THE FINDINGS & FURTHER RECOMMENDATIONS
Feline	Gastric wall aspirate - Suggestive of lymphoma with severe chronic secondary inflammation
BREED	COMMENTS
DSH	The cellularity in this collection is most characteristic of a lymphoma with extensive inflammation. There is another possibility of an inflammatory response with bacteria and fungal agents and a marked response from the lymphoid cells. The mixed cell collection is interfering with interpretation. A follow-up biopsy is encouraged since there is such a mixed cell reaction. I am concerned about lymphoma but a severe chronic inflammatory process is still possible. In my opinion, a guarded prognosis is warranted since the cellularity is variable.
SEX	
Male Neutered	
AGE	
11y	
WEIGHT	
13.8lbs	
HOSPITAL NAME	
Ruidoso Animal Clinic	
REFERRING VET	
Dr. Favis	
INVOICE NUMBER	
607	

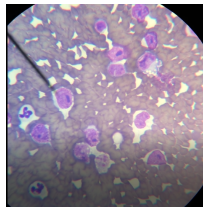


Image shows a field with more atypical lymphoid cells than other fields collected from the gastric wall in Zoey. Most of the neutrophils are non degenerate.

The information and recommendations provided are based on the images presented by the referring veterinarian. No evaluation can be communicated regarding pathology that was not visible in the image/video clips provided.

Thank you for this referral. If the clinical or image interpretation does not parallel your findings or if I can be of any further assistance please contact me.

L.D. McGill, DVM, Ph.D., DACVP
8288 Top of the World Drive
Cottonwood Heights, UT 84121
ldmcgill.vetpath@gmail.com
cell: 801-865-1220



DATE

10/7/21

INTERPRETED BY

L.D. McGill, DVM, Ph.D,
DACVP

PATIENT

Zoey Hutson

SPECIES

Feline

BREED

DSH

SEX

Male Neutered

AGE

11y

WEIGHT

13.8lbs

HOSPITAL NAME

Ruidoso Animal Clinic

REFERRING VET

Dr. Favis

INVOICE NUMBER

607