



DATE PRESENTING CLINICAL SIGNS

10/7/2021

Patient presents for possible BPH prostate/prostatic abscess.

CYTOLOGY SUBMISSION

U/S-guided FNA of prostate.

INTERPRETED BY

L.D. McGill, DVM,
Ph.D, DACVP

OBSERVATIONS

Prostate: Submitted are large numbers of excellent images and 3 videos of cells collected from the prostate in Leo. There is a uniformity throughout all of the images and videos. This uniformity consists of prosthetic epithelial cells that demonstrate rather uniform size and shape with uniform nuclei. There is minimal inflammation associated with this collection. There are no changes supporting malignant criteria.

PATIENT

Leo Terizzi

INTERPRETATION OF THE FINDINGS & FURTHER RECOMMENDATIONS

Prostate - Severe benign prostatic hyperplasia

SPECIES

Canine

COMMENTS

The cellularity in this collection is characteristic of benign prostatic hyperplasia. This is generally caused by hypertestosteronism or higher testosterone levels. This condition can easily be treated by neutering Leo. Without neutering, the prosthetic tissue will continue to undergo hyperplasia. I did not identify evidence of malignancy or sepsis. If there is no infection at this time, there likely will be infection in the future if this is not treated to eliminate the hyperplasia.

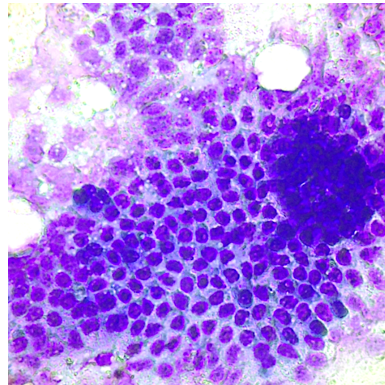
BREED

American Bulldog

Image below shows marked epithelial hyperplasia of the prostate. The uniformity supports hyperplasia.

SEX

Intact male



AGE

8-year-old

WEIGHT

74 lbs

HOSPITAL NAME

New Bridge VH

The information and recommendations provided are based on the images presented by the referring veterinarian. No evaluation can be communicated regarding pathology that was not visible in the image/video clips provided.

REFERRING VET

Dr. Glennon

Thank you for this referral. If the clinical or image interpretation does not parallel your findings or if I can be of any further assistance please contact me.

L.D. McGill, DVM, Ph.D., DACVP
8288 Top of the World Drive
Cottonwood Heights, UT 84121
ldmcgill.vetpath@gmail.com
cell: 801-865-1220



DATE

10/7/2021

INTERPRETED BY

L.D. McGill, DVM,
Ph.D, DACVP

PATIENT

Leo Terizzi

SPECIES

Canine

BREED

American Bulldog

SEX

Intact male

AGE

8-year-old

WEIGHT

74 lbs

HOSPITAL NAME

New Bridge VH

REFERRING VET

Dr. Glennon