



DATE PRESENTING CLINICAL SIGNS

10/6/22

FNA of very large SQ mass over L side. Bella has been on 5mg Prednisone EOD for several years for IBD and atopy. GI signs and acts nauseous when decrease dose. AUS overall unremarkable. PE: SQ mass, firm but smooth. Extends from elbow to mid-abdomen; spine down to ventral midline. AUS done, mass pushes body wall inwards and displaces spleen and SI caudally. Most of mass is homogenous echotexture, however ventral portion is cystic and irregular.

INTERPRETED BY

L.D. McGill, DVM,
Ph.D, DACVP

CYTOLOGY SUBMISSION

FNA of large SQ mass

PATIENT

Bella Walters

OBSERVATIONS

Large subcutaneous mass: Submitted are 7 excellent videos of excellent collections of cells from the subcutaneous mass on Bella. The cellularity is mixed. There are large numbers of macrophages with foamy cytoplasm. Lipid is prominent and is interspersed with large numbers of neutrophils some of which appear to be degenerate. There are one or two macrophages in the collection that suggest bacteria, but this was not a uniform observation. Malignant criteria were not identified.

SPECIES

Canine

BREED

Lab

INTERPRETATION OF THE FINDINGS & FURTHER RECOMMENDATIONS

Large subcutaneous mass - Severe chronic pyogranulomatous and necrotizing inflammation with fat tissue.

SEX

FS

COMMENTS

The cellularity in the smears is most consistent with a central necrotic and inflamed process within a proliferative lesion. With the fat tissue, I am suspicious of a necrotic lipoma which is quite large. The inflammatory process could be causing pressure due to fluid buildup and necrosis. The major cellularity will likely be on the margins of this mass. At this time, I suspect that most of our collection is from the center and is an inflammatory or necrotic process. Excision of the mass will likely be required to confirm the process. A repeat collection of the margins may be beneficial in Bella, as well. A guarded prognosis is warranted since the specific cellular proliferation has not been confirmed.

AGE

10 yr 10 mo

WEIGHT

99 lbs

HOSPITAL NAME

Scanvetl

REFERRING VET

Dr. Bennett

INVOICE NUMBER

40614



DATE

10/6/22

INTERPRETED BY

L.D. McGill, DVM,
Ph.D., DACVP

PATIENT

Bella Walters

SPECIES

Canine

BREED

Lab

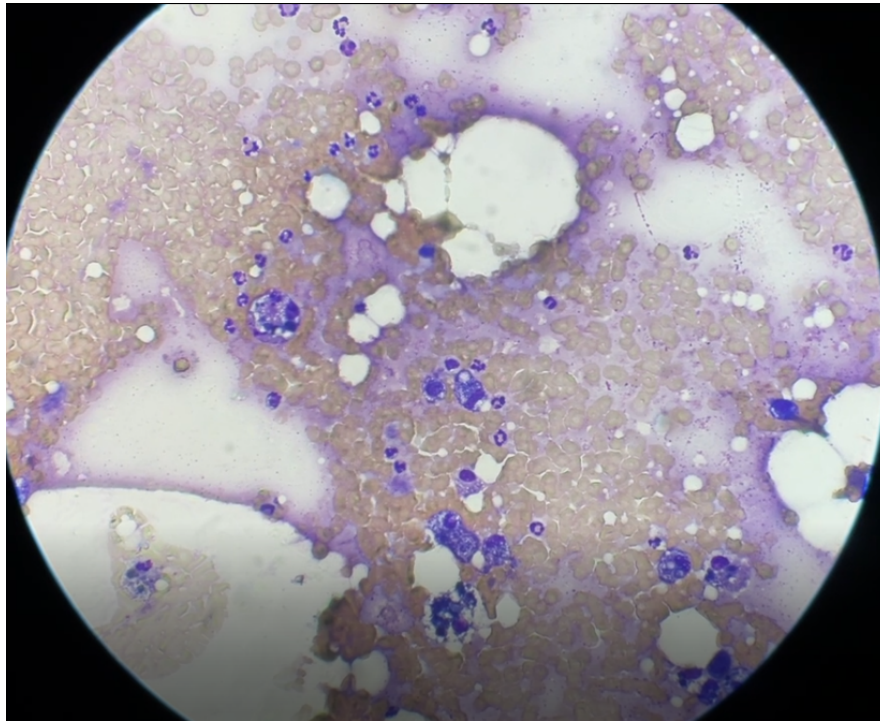


Image shows the macrophages with foamy cytoplasm with neutrophils and RBCs collected from the mass on Bella. Some of the reaction is very hemorrhagic.

SEX

FS

The information and recommendations provided are based on the images presented by the referring veterinarian. No evaluation can be communicated regarding pathology that was not visible in the image/video clips provided.

AGE

10 yr 10 mo

Thank you for this referral. If the clinical or image interpretation does not parallel your findings or if I can be of any further assistance, please contact me.

WEIGHT

99 lbs

L.D. McGill, DVM, Ph.D., DACVP
8288 Top of the World Drive
Cottonwood Heights, UT 84121
ldmcgill.vetpath@gmail.com
cell: 801-865-1220

HOSPITAL NAME

ScanvetI

REFERRING VET

Dr. Bennett

INVOICE NUMBER

40614