



**DATE** 10/5/22  
**PRESENTING CLINICAL SIGNS**  
Patient presented 10/3/22 for ADR. Ultrasound performed 10/5/22. Spleen enlarged. Liver enlarged and rounded. Liver aspirates attached. Spleen aspirates sent prior.

**INTERPRETED BY** L.D. McGill, DVM, Ph.D, DACVP  
**CYTOLOGY SUBMISSION**  
Liver

**PATIENT** Roxy Anderson  
**OBSERVATIONS**  
Liver: Submitted are 3 excellent videos of very good collections of hepatocytes and other cells from the liver in Roxy. The hepatocytes demonstrate vacuolization and slight granularity. There are scattered lymphoid cells. Some of the lymphocytes appear to be atypical. Others are small with scattered neutrophils.

**INTERPRETATION OF THE FINDINGS & FURTHER RECOMMENDATIONS**  
Liver - Hepatocellular vacuolization suggestive of early feline fatty liver syndrome with increased numbers of lymphoid cells.

**SPECIES** Feline  
**COMMENTS**  
The liver is likely enlarged due to early hepatocellular lipidosis. There are some lymphocytes which may be due to early lymphoma particularly since there is a prominent suggestion of that process in the spleen. The lymphoid cells may be due to lymphocytic inflammation but biopsies will be needed to confirm that process. A guarded to unfavorable prognosis is warranted due to the lymphoma in the spleen and the potential involvement of the liver secondarily.

**BREED** DSH

**SEX** Female Spayed

**AGE** 5y

**WEIGHT** 7.5#

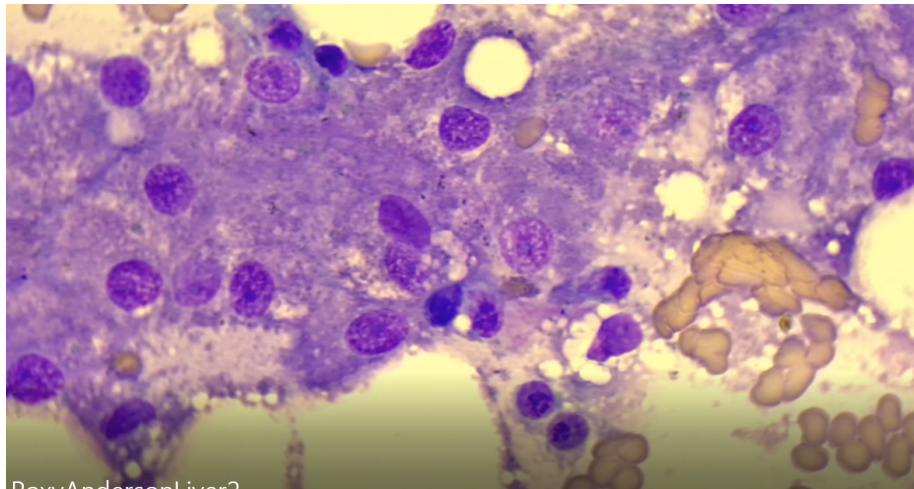


Image shows a field of hepatocytes collected from the liver in Roxy. Note the large lipid vacuoles and the lymphocytes particularly in the lower center.

**HOSPITAL NAME** Rotterdam Veterinary Hospital

**REFERRING VET** Dr. St. Sir

The information and recommendations provided are based on the images presented by the referring veterinarian. No evaluation can be communicated regarding pathology that was not visible in the image/video clips provided.

Thank you for this referral. If the clinical or image interpretation does not parallel your findings or if I can be of any further assistance please contact me.

**INVOICE NUMBER** 819



**DATE** L.D. McGill, DVM, Ph.D., DACVP

10/5/22  
8288 Top of the World Drive  
Cottonwood Heights, UT 84121  
ldmcgill.vetpath@gmail.com  
cell: 801-865-1220

**INTERPRETED BY**

L.D. McGill, DVM,  
Ph.D., DACVP

**PATIENT**

Roxy Anderson

**SPECIES**

Feline

**BREED**

DSH

**SEX**

Female Spayed

**AGE**

5y

**WEIGHT**

7.5#

**HOSPITAL NAME**

Rotterdam Veterinary  
Hospital

**REFERRING VET**

Dr. St. Sir

**INVOICE NUMBER**

819