



DATE **PRESENTING CLINICAL SIGNS**
10/5/22 Patient presented 10/3/22 for ADR, lethargic, vomiting, not eating. Patient had ultrasound done 10/5/22. Spleen was enlarged on ultrasound. Liver enlarged and rounded. Aspirate videos of liver to follow.

INTERPRETED BY **CYTOLOGY SUBMISSION**
L.D. McGill, DVM, Ph.D, DACVP Spleen

PATIENT **OBSERVATIONS**
Roxy Anderson Spleen: Submitted are 6 excellent videos of excellent collections of cells from the spleen in Roxy. There is one video that includes a microfilaria but the others all have large numbers of round cells. The round cells are characteristic of lymphoid cells and many of those cells are quite large. There are fields where the nuclei have prominent nucleoli with minimal cytoplasm. Where the cytoplasm is prominent, it is bluish gray. There are scattered small lymphocytes throughout the collection but the majority of the cells are large irregular atypical lymphoid cells.

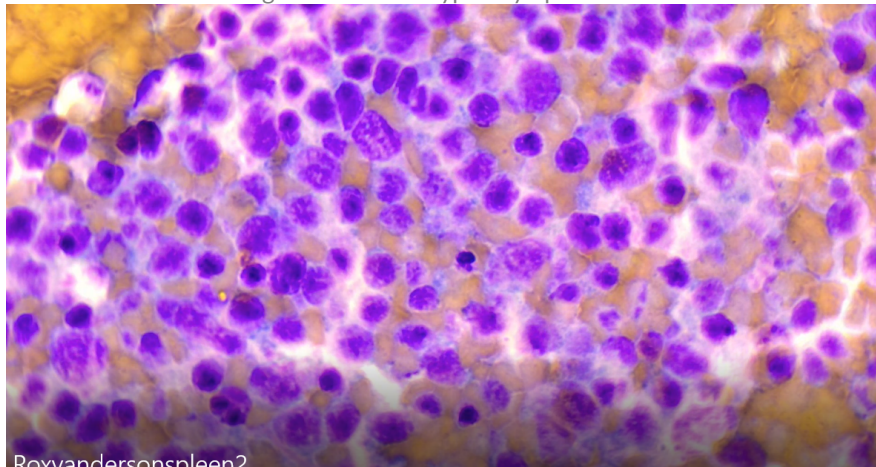
SPECIES **INTERPRETATION OF THE FINDINGS & FURTHER RECOMMENDATIONS**
Feline Spleen - Consistent with high-grade lymphoma with a microfilaria.

BREED **COMMENTS**
DSH The cellularity in the spleen supports a high-grade lymphoma in this location. Immunophenotyping the cells can be beneficial in confirming the diagnosis and potentially identifying immunophenotype. There is some secondary degeneration. The cellularity is quite prominent for a high-grade lymphoma. The microfilaria suggest the possibility of heartworm infestation in Roxy. An unfavorable prognosis is warranted due to the large numbers of atypical lymphoid cells in this collection.

SEX
Female Spayed

AGE
5y

WEIGHT
7.3#



Roxyandersonspleen2

HOSPITAL NAME Image shows a representative collection of cells from the spleen in Roxy. Note the large number of large atypical cells.
Rotterdam Veterinary Hospital

REFERRING VET The information and recommendations provided are based on the images presented by the referring veterinarian. No evaluation can be communicated regarding pathology that was not visible in the image/video clips provided.

Dr. St. Sir Thank you for this referral. If the clinical or image interpretation does not parallel your findings or if I can be of any further assistance please contact me.

INVOICE NUMBER
819



DATE L.D. McGill, DVM, Ph.D., DACVP

10/5/22
8288 Top of the World Drive
Cottonwood Heights, UT 84121
ldmcgill.vetpath@gmail.com
cell: 801-865-1220

INTERPRETED BY

L.D. McGill, DVM,
Ph.D., DACVP

PATIENT

Roxy Anderson

SPECIES

Feline

BREED

DSH

SEX

Female Spayed

AGE

5y

WEIGHT

7.3#

HOSPITAL NAME

Rotterdam Veterinary
Hospital

REFERRING VET

Dr. St. Sir

INVOICE NUMBER

819