



**DATE PRESENTING CLINICAL SIGNS**

10/5/21

The owner picked the dog from the boarding 2 days ago. The dog has reduced appetite since then. He noticed some swollen skin in the right groin region. The dog was very painful in that region. No vomiting or diarrhea. But the dog has reduced fecal output

**INTERPRETED BY**

L.D. McGill, DVM,  
Ph.D, DACVP

BAR in the consult. I found an erythemic crusty area of skin in the right groin region, most likely a pyoderma. The dog would not allow to touch this region because of pain. Rest of the physical examination was unremarkable. Anemia (low HCT) was found as an incidental finding.

RBC count was within the normal limits ( $5.51 \times 10^{12}/l$ )

HCT :25.29

MCV : 46

**PATIENT**

The biochemistry panel was normal and no obvious reason for hyporexia could be found

Arkyn Hamad

**CYTOLOGY SUBMISSION**

Cyto blood smear and impression smear from the skin

**SPECIES**

Canine

**OBSERVATIONS**

Blood smear: Submitted is a single video of several fields in the blood smear from Arkyn. There are excellent red blood cells throughout the smears. Leukocytes are few and include an eosinophil, neutrophils and some lymphocytes. The RBCs demonstrate minimal polychromasia but a more prominent hypochromasia throughout. There are few cells that suggest the possibility of spherocytes but they are not numerous. The fields appear to be mixed and not one specific appearance throughout all of these images.

**BREED**

American Akita

Skin smear: Submitted is a single video of several fields of cells collected from the skin lesion on Arkyn. There is a consistent pattern of cellularity throughout the smears. There are large numbers of neutrophils with many of them undergoing degeneration. There are prominent bacteria in the background. The bacteria have a coccobacillus pattern on the smears. Specific other organisms are not identified. There are some fields that could suggest the possibility of fungal hyphae but I could not confirm that observation. There is no suggestion of malignancy.

**SEX**

Male Intact

**AGE**

5 month 23 days

**INTERPRETATION OF THE FINDINGS & FURTHER RECOMMENDATIONS**

Blood smear - Hypochromasia with minimal response to support regeneration and mild inflammation.

Skin smear - Marked bacterial growth with neutrophilic inflammation consistent with severe pyoderma.

**WEIGHT**

37.3kg

**COMMENTS**

The blood smear supports hypochromasia and the MCV suggests cells with minimal hemoglobin present. Anything under 60 MCV is a concern for hypochromasia and potential iron deficiency anemia. I am concerned about Arkyn having intestinal bleeding. This can be evaluated by doing a fecal occult blood evaluation. If that is negative, then Arkyn is losing blood in a chronic manner somewhere. I would be surprised if this was another potential lead poisoning case like the kitten. The skin lesion supports a rather severe pyoderma. There are large numbers of bacteria scattered throughout. The neutrophils are degenerate. I am always concerned with this type of lesion about the potential of methicillin resistant organisms. Bacterial culture and treatment is certainly in order for

**HOSPITAL NAME**

City Veterinary Clinic  
Alainl

**REFERRING VET**

Dr. Inam ul haq

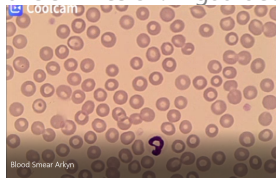**INVOICE NUMBER**

70415



**DATE** this skin lesion. A guarded prognosis is warranted due to the hypochromasia and low MCV.

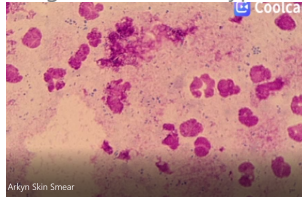
10/5/21



**INTERPRETED BY**

L.D. McGill, DVM,  
Ph.D, DACVP

Image shows some hypochromasia in the blood smear from Arkyn..



**PATIENT**

Arkyn Hamad

Image shows neutrophils, most are degenerate. Lots of bacteria in the background. The amorphous material may have hyphae but can't confirm. Just may be necrotic debris collected from Arkyn.

**SPECIES**

Canine

**The information and recommendations provided are based on the images presented by the referring veterinarian. No evaluation can be communicated regarding pathology that was not visible in the image/video clips provided.**

**BREED**

American Akita

Thank you for this referral. If the clinical or image interpretation does not parallel your findings or if I can be of any further assistance please contact me.

**SEX**

Male Intact

**L.D. McGill, DVM, Ph.D., DACVP**  
8288 Top of the World Drive  
Cottonwood Heights, UT 84121  
ldmcgill.vetpath@gmail.com  
cell: 801-865-1220

**AGE**

5 month 23 days

**WEIGHT**

37.3kg

**HOSPITAL NAME**

City Veterinary Clinic  
Alainl

**REFERRING VET**

Dr. Inam ul haq

**INVOICE NUMBER**

70415