

DATE PRESENTING CLINICAL SIGNS

10/4/22

Patient presented for red, hard, swollen nipple 9/16/22. On exam, left mid abdominal nipple was somewhat enlarged, red, bloody discharge. Impression smear showed neutrophils and cocci bacteria. Patient started on ABs. Recheck two weeks later shows nipple is still red and swollen with slight firmness. FNAs taken and videos attached.

INTERPRETED BY

L.D. McGill, DVM,
Ph.D, DACVP

CYTOLOGY SUBMISSION

FNA of Mammary lesion

PATIENT

Lexi Putorti

OBSERVATIONS

Mammary lesion: Submitted are 3 excellent videos of moderate to excellent collections of cells from the mammary lesion in Lexi. There is a background of red blood cells. There are scattered aggregates of cells that demonstrate an epithelial pattern since they are aggregated. They demonstrate mild anisocytosis and anisokaryosis. There are scattered inflammatory cells associated with this collection. The cellularity in these collections does not have an aggressive pattern.

SPECIES

Canine

BREED

Pitbull

INTERPRETATION OF THE FINDINGS & FURTHER RECOMMENDATIONS

Mammary mass - Suggestive of mammary gland adenoma.

SEX

SF

COMMENTS

The cellularity in this collection is suggesting an epithelial cell proliferation but it is not demonstrating carcinomatous patterns in these collections. It is more characteristic of a mammary gland adenoma. In the dog this is more common than carcinomas, but carcinomas of course do occur. In this instance it appears that the growth is a proliferative process and should be excised. These growths can become more aggressive, and inflammation can cause more problems in the region. Wide excision of this mass or any other masses in the mammary gland region is encouraged. A good if completely excised prognosis is expected in my opinion with this cellularity.

AGE

11y

WEIGHT

68#

HOSPITAL NAME

Rotterdam Veterinary
Hospital

REFERRING VET

Dr. Melodee Kopa

INVOICE NUMBER

40611



DATE

10/4/22

INTERPRETED BY

L.D. McGill, DVM,
Ph.D., DACVP

PATIENT

Lexi Putorti

SPECIES

Canine

BREED

Pitbull

SEX

SF

AGE

11y

WEIGHT

68#

HOSPITAL NAME

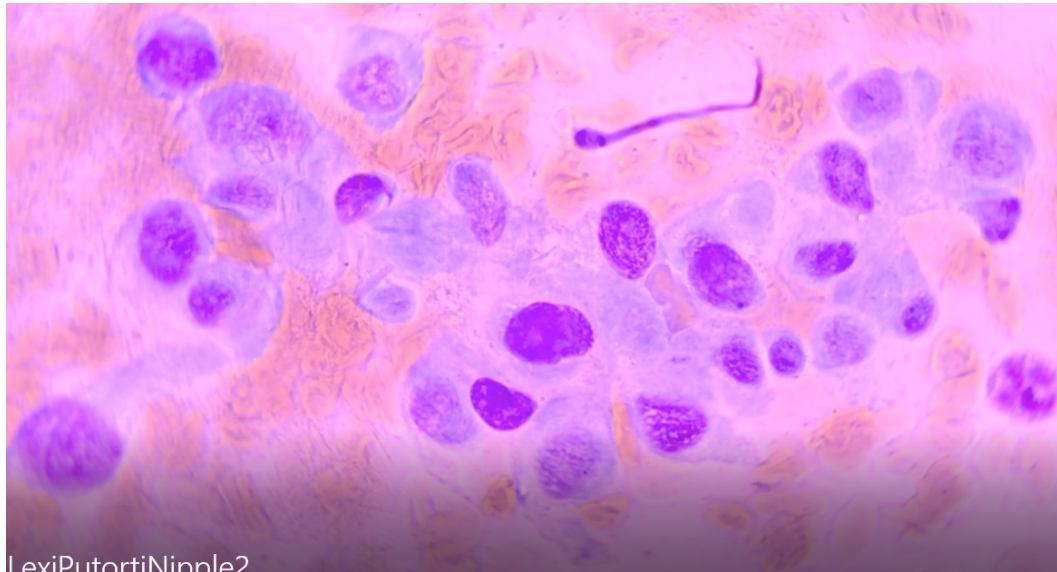
Rotterdam Veterinary
Hospital

REFERRING VET

Dr. Melodee Kopa

INVOICE NUMBER

40611



LexiPutortiNipple2

Image shows a group of epithelial cells with 1 or 2 inflammatory cells collected from the mammary lesion on Lexi. There is a lymphocyte in the upper left and a neutrophil in the lower right.

The information and recommendations provided are based on the images presented by the referring veterinarian. No evaluation can be communicated regarding pathology that was not visible in the image/video clips provided.

Thank you for this referral. If the clinical or image interpretation does not parallel your findings or if I can be of any further assistance, please contact me.

L.D. McGill, DVM, Ph.D., DACVP
8288 Top of the World Drive
Cottonwood Heights, UT 84121
ldmcgill.vetpath@gmail.com
cell: 801-865-1220