

10/4/21

INTERPRETED BY

L.D. McGill, DVM, Ph.D., DACVP

PRESENTING CLINICAL SIGNS

Bilateral pericocular alopecia which developed following the food change. The dog received bravecto tablet about a month ago. The owner did not agree to the diagnostic evaluation in the first consult. I placed the dog on cefalexin twice per day for 10 days. Today, the owner came for a follow up. The left eye had increased alopecia and was more itchy on that eye. I took impression smears from both eyes. I also took skin scrap but did not see any ectoparasites in that.

PATIENT

Rami Lilly

Bilateral pericocular alopecia was noticed. The foot pads of both forelimbs showed hyperkeratosis and there was erythema of both ear pinna. The axilla were mildly erythemic

CYTOLOGY SUBMISSION

Skin

SPECIES

Canine

OBSERVATIONS

Skin: Submitted is 1 short video and gross photos of skin lesions on Rami. The cellularity on the skin collections consists mainly of superficial keratinized cells with one or two lymphocytes and possibly some macrophages. There may have been one polymorphonuclear cell. The cellularity is minimal to suggest a specific process.

BREED

Jack Russel

INTERPRETATION OF THE FINDINGS & FURTHER RECOMMENDATIONS

Skin - Superficial cellularity with no specific cellular changes noted.

SEX

Female

COMMENTS

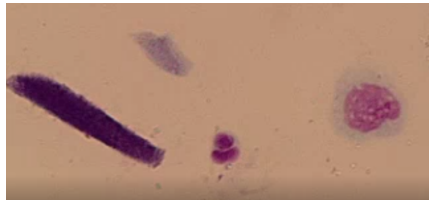
With the cellularity and the gross photos and the clinical description, I am suspicious of some type of allergic reaction. It could be food allergy or even drug oriented. I did not identify eosinophils. Deeper aspiration of these areas immediately beneath the epithelium may be beneficial. Drug eruption could also result in lymphocytes as part of response. With this very superficial collection, I would not expect any changes that would support neoplasia in this collection. Continued monitoring for allergic disease processes is encouraged. I was unable to identify any suggestion of bacterial infection. If problems continue and the diagnosis is required, then follow-up skin biopsies would be encouraged.

AGE

1yr11mo

WEIGHT

4.2



HOSPITAL NAME

City Veterinary Clinic Alain

Image shows 2 keratinized cells, a macrophage and polymorphonuclear cell collected from Rami.

The information and recommendations provided are based on the images presented by the referring veterinarian. No evaluation can be communicated regarding pathology that was not visible in the image/video clips provided.

Thank you for this referral. If the clinical or image interpretation does not parallel your findings or if I can be of any further assistance please contact me.

REFERRING VET

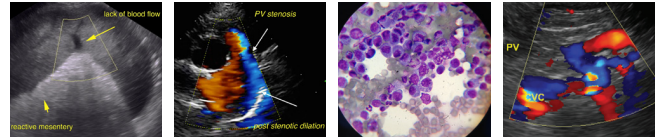
Inam ul haq

L.D. McGill, DVM, Ph.D., DACVP

8288 Top of the World Drive
Cottonwood Heights, UT 84121
ldmcgill.vetpath@gmail.com
cell: 801-865-1220

INVOICE NUMBER

606



EDUCATIONAL TELECONSULTATION SERVICES™
DATE

SonoPath.com
1-800-838-4268 info@sonopath.com

10/4/21

INTERPRETED BY

L.D. McGill, DVM, Ph.D,
DACVP

PATIENT

Rami Lilly

SPECIES

Canine

BREED

Jack Russel

SEX

Female

AGE

1yr11mo

WEIGHT

4.2

HOSPITAL NAME

City Veterinary Clinic Alain

REFERRING VET

Inam ul haq

INVOICE NUMBER

606