



**DATE PRESENTING CLINICAL SIGNS**

10/31/21 Not FNA of Liver  
ABNORMAL Laboratory Findings Alt 327 n=10-125 alk phos  
1868 n= 21-212 amyl 1856 n=500-1500 lipa 2222 n=200-1800

**INTERPRETED BY CYTOLOGY SUBMISSION**

L.D. McGill, DVM,  
Ph.D, DACVP

Liver

**OBSERVATIONS**

Liver: Submitted are 4 excellent videos of minimal to moderate cellularity collected from the liver in Abby. The cellularity includes a very few collections of hepatocytes. There are large numbers of RBCs surrounding the hepatocytes with a mixture of neutrophils, lymphocytes and macrophages. There are no changes that would suggest neoplasia. There is some suggestion of mild inflammation in the surrounding red blood cells. The few hepatocytes present demonstrate slight granularity and vacuolization. Malignant characteristics are not identified.

**SPECIES INTERPRETATION OF THE FINDINGS & FURTHER RECOMMENDATIONS**

Canine

Liver - Mild hepatocellular vacuolization and granularity with mild inflammation in the surrounding tissue.

**BREED COMMENTS**

Labrador

The changes in this tissue are not specific for any primary process and there certainly is no suggestion of neoplasia. Sepsis is not suggested either. These types of changes could be secondary to other problems in other organs including pancreatitis or enteritis. These changes may also be due to maturation of the hepatocellular membranes with a nonspecific change. The membranes may begin leaking and result in some of the enzyme changes described. This is not a specific pathologic change. If problems continue, continued monitoring of other organs or a follow-up liver biopsy may be beneficial.

**SEX**

Female Spayed

**AGE**

14yr

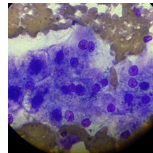


Image shows hepatocellular vacuolization and granularity is a small group of hepatocytes collected from Abby. The cellularity is not specific. There is no suggestion of neoplasia.

**WEIGHT**

88.8lbs

The information and recommendations provided are based on the images presented by the referring veterinarian. No evaluation can be communicated regarding pathology that was not visible in the image/video clips provided.

**HOSPITAL NAME**

Pawsitive Wellness  
Veterinary Carel

Thank you for this referral. If the clinical or image interpretation does not parallel your findings or if I can be of any further assistance please contact me.

**REFERRING VET**

Dr. Popuette

L.D. McGill, DVM, Ph.D., DACVP  
8288 Top of the World Drive  
Cottonwood Heights, UT 84121  
ldmcgill.vetpath@gmail.com  
cell: 801-865-1220

**INVOICE NUMBER**

626



**DATE**

10/31/21

**INTERPRETED BY**

L.D. McGill, DVM,  
Ph.D, DACVP

**PATIENT**

Abby Lewis

**SPECIES**

Canine

**BREED**

Labrador

**SEX**

Female Spayed

**AGE**

14yr

**WEIGHT**

88.8lbs

**HOSPITAL NAME**

Pawsitive Wellness  
Veterinary Care

**REFERRING VET**

Dr. Popuette

**INVOICE NUMBER**

626