



DATE PRESENTING CLINICAL SIGNS

10/27/21

Persistent lethargy, weight loss over past 3 weeks, painful abdomen, previous vomiting (~2-3 days ago) and development of colitis (mucous, hematochezia and tenesmus); present for 2-3 days. Physical exam: Quiet, slightly lethargic, responsive. Temp: 103.4 F Mild abdominal tensing, mild crusting at the vulva, however no active discharge. Slight stricture at the os of the vulva. Watery, brown stool from rectal.

INTERPRETED BY

L.D. McGill, DVM,
Ph.D, DACVP

Blood work at BAESC:
10/24/21: Glob: 5.2 g/dL (2.5-4.5) Monocytosis: 1900/uL (160-1120) Protein serum electrophoresis submitted: pending
10/22/21 at Tumalo Animal Hospital:

PATIENT

Kayla Bowers

bloodwork and rads - only findings a stress leukogram and mildly elevated globulins. Rads show diffuse gas in GI - consistent with enteritis, no obvious obstruction or mass noted.

CYTOLOGY SUBMISSION

FNA of Liver & Spleen

SPECIES

Canine

OBSERVATIONS

Liver: Submitted are 4 excellent videos of cells collected from the liver in Kayla. There are good collections of hepatocytes in many fields. The hepatocytes are rather consistent with granularity of the cytoplasm and normal size and shape. There are scattered inflammatory cells associated with hepatocytes and in the surrounding red blood cells. Neutrophils are readily identified. There are some lymphocytes in the surrounding red blood cells. Malignant criteria are not identified.

BREED

German Shepherd

Spleen: Submitted are 4 excellent videos of cells collected from the spleen in Kayla. The cellularity in general is mixed with neutrophils, nucleated RBCs and some lymphoid cells. There are several fields in one of the videos that include large numbers of lymphoid cells. The lymphoid cells have some atypical patterns of cellularity. This causes concern about lymphoma in the case. This was not diffuse throughout all of the cellular collections, but those cells may be part of the process in other locations as well. The majority of the reaction in the videos is inflammatory and chronic in nature.

SEX

F I

INTERPRETATION OF THE FINDINGS & FURTHER RECOMMENDATIONS

Liver - Hepatocellular granularity with mild chronic inflammation.

AGE

7 years

Spleen - Mixed cell collection through most of the videos with one area demonstrating increased numbers of atypical lymphoid cells suggesting early lymphoma.

COMMENTS

WEIGHT

32.4 kg

The changes in the liver support a mild chronic inflammatory process. Leptospirosis could easily be an underlying cause for that type of inflammation. There is no suggestion of neoplasia in any of the cells collected from the liver. Chronic inflammation can occur secondarily to problems in the intestine or even the pancreas.

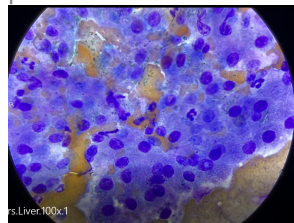
HOSPITAL NAME

Tumalo Animal Hospital

The changes in the spleen are somewhat more problematic. There are many changes that support chronic inflammation in the spleen but there are fields that cause concern about early lymphoma. Some of those cells could be present in other fields and be difficult to differentiate. Further workup of Kayla for the potential of lymphoma in other organs is encouraged. Your description certainly does not rule that diagnosis out. Leptospirosis or other forms of intestinal inflammation could be part of the process.

REFERRING VET

Dr. Blair Westbrook



INVOICE NUMBER

70418



DATE Image shows representative hepatocytes with granularity and scattered neutrophils associated with the hepatocytes collected from Kayla.

10/27/21

INTERPRETED BY

L.D. McGill, DVM,
Ph.D, DACVP

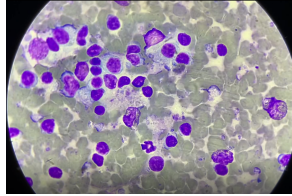


Image shows representative atypical lymphoid cells with a few intermediate lymphocytes in one of the fields with irregular lymphoid cells from the spleen in Kayla.

PATIENT

Kayla Bowers

The information and recommendations provided are based on the images presented by the referring veterinarian. No evaluation can be communicated regarding pathology that was not visible in the image/video clips provided.

SPECIES

Canine

Thank you for this referral. If the clinical or image interpretation does not parallel your findings or if I can be of any further assistance, please contact me.

BREED

German Shepherd

L.D. McGill, DVM, Ph.D., DACVP
8288 Top of the World Drive
Cottonwood Heights, UT 84121
ldmcgill.vetpath@gmail.com
cell: 801-865-1220

SEX

F I

AGE

7 years

WEIGHT

32.4 kg

HOSPITAL NAME

Tumalo Animal Hospital

REFERRING VET

Dr. Blair Westbrook

INVOICE NUMBER

70418