



DATE PRESENTING CLINICAL SIGNS

10/26/21 Increasing liver values.
Current meds: Amoxicillin, Apoquel

INTERPRETED BY CYTOLOGY SUBMISSION

Liver

L.D. McGill, DVM,
Ph.D, DACVP

OBSERVATIONS

Liver: Submitted are 3 excellent videos of good collections of cells from the liver in Wampum. The cells consist of excellent collections of hepatocytes that demonstrate vacuolization and granularity. The hepatocytes are irregular in size and shape. Nuclei are slightly pleomorphic. There are scattered binucleated cells. There is a mixture of inflammatory cells associated with hepatocytes and the surrounding RBCs. Malignant criteria are not identified.

PATIENT

Wampum Letki

INTERPRETATION OF THE FINDINGS & FURTHER RECOMMENDATIONS

Liver: Hepatocellular vacuolization and granularity with mild chronic inflammation.

SPECIES

Canine

COMMENTS

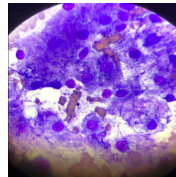
The hepatocytes demonstrate slight irregularity with some vacuolization. Occasionally this vacuolization can indicate copper deposition. There is mild inflammation associated with these hepatocytes. I cannot confirm malignancy. Biopsy of the liver tissue may be required to confirm what is occurring in the liver tissue. This easily could be a case of chronic inflammatory hepatopathy with secondary vacuolization. These changes could also be related to problems in other organs such as the pancreas or intestine. If problems continue, then follow-up liver biopsies can be considered. There are many cases in older dogs where the hepatocellular membranes become weak and leak enzymes even though there are no primary pathologic changes in the liver.

BREED

Lab Mix

SEX

Female Spayed



AGE

11yr

Image shows representative hepatocytes with vacuolization and granularity. The cells are irregular in size and shape.

WEIGHT

58.4 lbs

The information and recommendations provided are based on the images presented by the referring veterinarian. No evaluation can be communicated regarding pathology that was not visible in the image/video clips provided.

HOSPITAL NAME

Newton Veterinary
Hospital

Thank you for this referral. If the clinical or image interpretation does not parallel your findings or if I can be of any further assistance please contact me.

L.D. McGill, DVM, Ph.D., DACVP

8288 Top of the World Drive
Cottonwood Heights, UT 84121
ldmcgill.vetpath@gmail.com
cell: 801-865-1220

REFERRING VET

Dr. Wyman-Greenwald

INVOICE NUMBER

618



DATE

10/26/21

INTERPRETED BY

L.D. McGill, DVM,
Ph.D, DACVP

PATIENT

Wampum Letki

SPECIES

Canine

BREED

Lab Mix

SEX

Female Spayed

AGE

11yr

WEIGHT

58.4 lbs

HOSPITAL NAME

Newton Veterinary
Hospital

REFERRING VET

Dr. Wyman-Greenwald

INVOICE NUMBER

618